



# Impact of Mangosteen Rind on TNF- $\alpha$ Level of Diabetic Wound Healing

Lanny Sunarjo<sup>1,3\*</sup>, Oedijani<sup>1</sup>, Suharti<sup>1</sup>, Henry Setyawan Susanto<sup>2</sup> and Diyah Fatmasari<sup>3</sup>

## Abstract

**Background:** Diabetic wound healing process has many obstacles including inflammatory response. A strategy accelerates diabetic wound healing by controlling level of pro-inflammatory cytokine (TNF- $\alpha$ ). Mangosteen rind as anti-inflammatory potentially accelerates diabetic wound healing. There is lack of study about mangosteen rind towards TNF- $\alpha$  level of diabetic wound healing.

**Objective:** To prove impact of mangosteen rind extract (MRE) topically on TNF- $\alpha$  level of diabetic-type 1 wound healing post tooth extraction in rat.

**Method:** Experiment with randomized pre-post test with control group design. Sample was 40 male Wistar rats aged 8-10 weeks, weight 120-160 g, divided into 4 groups: diabetic wound treated MRE; diabetic wound control; non-diabetic wound treated MRE and non-diabetic wound control. Preparation of type 1 diabetic rats using induction of Streptozotocin (STZ) 1x with dose of 50 mg/kg intraperitoneal. Rat with diabetes when blood glucose at fasting time (hyperglycemia)  $\geq$  250 mg/dl. Diabetic wound was made by extraction of right upper incisor, as well as in non-diabetic wound. Monitoring of diabetic wound healing was by TNF- $\alpha$  level in inflammatory phase. Data was analyzed by General Linear Model test.

**Result:** TNF- $\alpha$  level of diabetic wound treated MRE was only 50% of control group and there was a significant difference between diabetic wound group ( $p < 0.05$ ), TNF- $\alpha$  level decreased 40% in inflammatory phase.

**Conclusion:** Mangosteen rind extract topically reduced and controlled TNF- $\alpha$  level in inflammatory phase and accelerated diabetic-type 1 wound healing post tooth extraction in rat.

**Key Words:** Male Wistar Rat, Mangosteen Rind, Diabetic Wound Healing, TNF- $\alpha$ .

**DOI Number:** 10.14704/nq.2020.18.2.NQ20142

**NeuroQuantology 2020; 18(2):173-179**

173

## Preliminary

### A. Research Background

Chronic wound healing, a major complication in diabetic patient is still a serious clinical problem<sup>(1)</sup>. A population-based study in the United States on prevalence and cost of treatment indicated prevalence of 3 (three) major types of wound not recovered was estimated between 3-6 million<sup>(2)</sup>. Chronic wound resulted in expenditure for very large medical cost with a total estimated  $\geq$  \$ 3 billion rupiah per year. Mechanism of diabetic wound healing including disorder of inflammation response<sup>(3-5)</sup>, growth factor<sup>(3, 6, 7)</sup>, angiogenesis response<sup>(3, 8)</sup>, macrophage function<sup>(9)</sup>, collagen

deposit, epidermal function, granulation tissue<sup>(3)</sup>, keratinocyte, fibroblast migration and proliferation, epidermal nerve number<sup>(10)</sup>, bone healing and balancing between ECM (Extracellular Matrix) component accumulation and remodeling by MMPs (Matrix Metalloproteinases)<sup>(11)</sup>. One approach could be made to improve diabetic wound healing by controlling inflammation including TNF- $\alpha$  level as a major proinflammatory cytokine<sup>(6)</sup>.

**Corresponding author:** Lanny Sunarjo

**Address:** <sup>1</sup>Fakultas Kedokteran, Universitas Diponegoro Semarang, Indonesia; <sup>2</sup>Fakultas Kesehatan Masyarakat, Universitas Diponegoro Semarang, Indonesia; <sup>3</sup>Poltekkes Kemenkes Semarang, Indonesia.

\*E-mail: lannysunarjo@gmail.com

**Relevant conflicts of interest/financial disclosures:** The authors declare that the research was conducted in the absence of any commercial or financial relationships that could be construed as a potential conflict of interest.

**Received:** 13 January 2020 **Accepted:** 10 February 2020



Uncontrolled inflammatory response may cause tissue damage therefore controlling inflammation was essential to optimize wound healing process (12). Expression of TNF- $\alpha$  has been shown to be highly elevated during inflammatory phase in wound healing process (13). TNF- $\alpha$  (major proinflammatory cytokine) is produced by macrophage, T cell and immune cell in early wound with relatively high concentration. At low level, TNF- $\alpha$  could promote wound healing by stimulating inflammation indirectly and macrophage in producing growth factor. However, at high level (excessive) and especially in prolonged period may cause septic shock and cell damage in inflammatory process, TNF- $\alpha$  may harm healing effect by suppressing synthesis of extracellular matrix protein (ECM) and as inhibitor of metalloproteinases (TIMPs) as well increasing synthesis of matrix metalloproteinases (MMPs) (14). Significant increases in TNF- $\alpha$  level could be caused by infection (15).

Oral care can be performed in diabetic patient including operative dentistry such as oral surgery, curettage and tooth extraction although higher risk than non-diabetic patient. Currently, standard therapy given post tooth extraction is provision of antibiotic, anti-inflammatory, anti pain and topical medicine. Chemical topical preparation serving to relieve pain, control bleeding and assist blood clotting processes on the market including silver nitrate, gelatine-based haemostats, collagen-based haemostats, fibrin-based haemostats, anti fibrinolysis and bismuth subgallate. This preparation has not been specifically for diabetic patient where the healing process ran more slowly with higher incidence of complication such as infection, poor tissue perfusion (ischemia) and neuropathy resulting in reduced oxygen pressure and nutrient supply, hypoxia and small blood vessel dysfunction (2). Therefore, other alternative ingredient such as herbal ingredient relatively cheaper, efficient, easy to use and supporting policy of local government program aiming to maximize natural cultivation. Herbal medicine played an important role in treatment of diabetes, especially developing countries because of its cost-efficient (16).

Mangosteen is an Indonesian native plant easy to find and cheap price in market and has been widely used for wound healing treatment, especially for diabetes. Research conducted (17) stated MRE with a dose of 100 mg/kg weight may reduce blood

glucose level in rat. Clinically MRE accelerated healing of periodontal treatment (18). Preliminary study had been conducted by researcher (19) using topical MRE preparation as a remedy for oral traumatic ulcer. Furthermore, a study analyzing of testing material MRE stated that 100 gr of MRE positively contained 0.16% xanthone and 0.74% mangostin (20). Xanthone able to act as anti-inflammatory (21). One of topical therapeutic benefit was direct drug delivery to wound site at optimum concentration with minimal risk of systemic side effect and no oral mucosa permeability barrier (22). This study may prove effect of MRE topically on TNF- $\alpha$  level in diabetic wound healing post tooth extraction.

## Research Methods

### A. Research Design

An experimental research with randomized pre-post test with control group design using laboratory test.

### B. Research Variables and Operational Formulations

1. The modeling of diabetic-type 1 wound (23-26) in oral cavity:
  - Induction of Streptozotocin (STZ) 1x with dose of 50 mg/kg intraperitoneal.
  - Diabetic rat when blood glucose at the time of fasting (hyperglycemia)  $\geq$  250 mg/dl.
  - Extraction of 1 (one) tooth incisive upper right.
2. Plant Testing Material (20):
  - Determination of mangosteen type was *Garcinia mangostana* L with main active ingredients xanthone and mangostin.
  - Preparation of plant material obtained by extracting mangosteen rind using maceration method.
  - Acute toxicity and microbiology tests were performed for safety and toxicity of mangosteen rind extract preparation, if not toxic and then applied topically to diabetic wound.
3. Measurement of TNF- $\alpha$  level was 2 ml blood of retro-orbital sinus (28) in centrifuge, if not directly examined, this serum was stored in freezers -4 $^{\circ}$ C to -20 $^{\circ}$ C for testing on day to 0, 3 and 7 with ELISA Kit.



**C. Population and Samples**

**Animal Experimentation**

A simple randomized male Wistar Rat, there are 40 rats (aged 8-10 weeks, weight 120-160 g) divided into 4 groups: Diabetic Wound Treated MRE; Diabetic Wound Control; Non-Diabetic Wound Treated MRE and Non-Diabetic Wound Control

**D. Data Analysis Techniques**

Initial data analyzed with Kolmogorov-Smirnov test, TNF- $\alpha$  level data was not normal, bivariate analysis using Wilcoxon signed rank test to determine impact of mangosteen rind extract topically against TNF- $\alpha$  level in diabetic wound healing post tooth extraction. All analyzes were assisted with a computer through the SPSS for Windows.

**Results and Discussion**

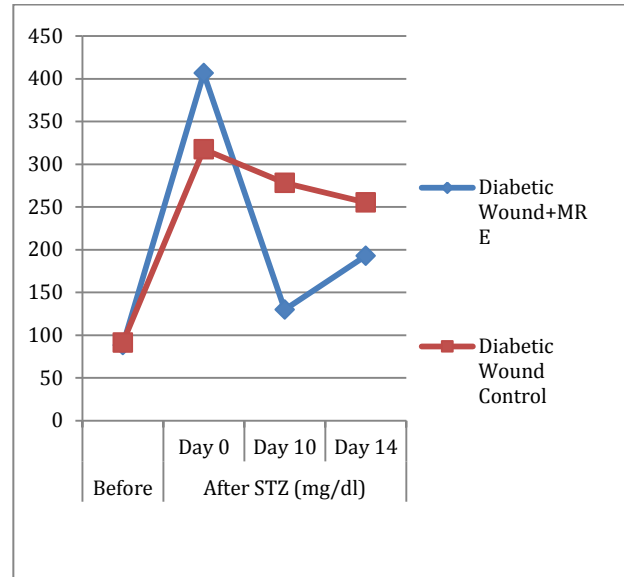
**A. Research Results**

Blood glucose level of rat diabetic before and after administration STZ was shown in Table 1. and Figure 1. There were shown that those diabetic rats when blood glucose at the time of fasting (hyperglycemia)  $\geq 250$  mg/dl.

**Table 1.** Blood Glucose Level Before and After Administration STZ

Group	Early Blood Glucose (mg/dl)	Blood Glucose After Administration STZ (mg/dl)		
		Day 0	Day 10	Day 14
Diabetic Wound+MRE	88,30	406,50	129,80	192,80
Diabetic Wound Control	91,30	317,50	278,20	255,40

Table 1. showed average blood glucose level in diabetic wound treated MRE group increased 4.5 times from 88.30 mg/dl to 406.50 mg/dl on day 0 after administration of STZ and then decreased about 75 % on day 10 (129.80 mg/dl) and 50% at day 14 (192.80 mg/dl). While average blood glucose level in diabetic wound control group increased 3.5 times from 91.30 mg/dl to 317.50 mg/dl on day 0 after STZ administration and then slightly decrease (10%) on day 10 (278.20 mg/dl) and day 14 (255.40 mg/dl).

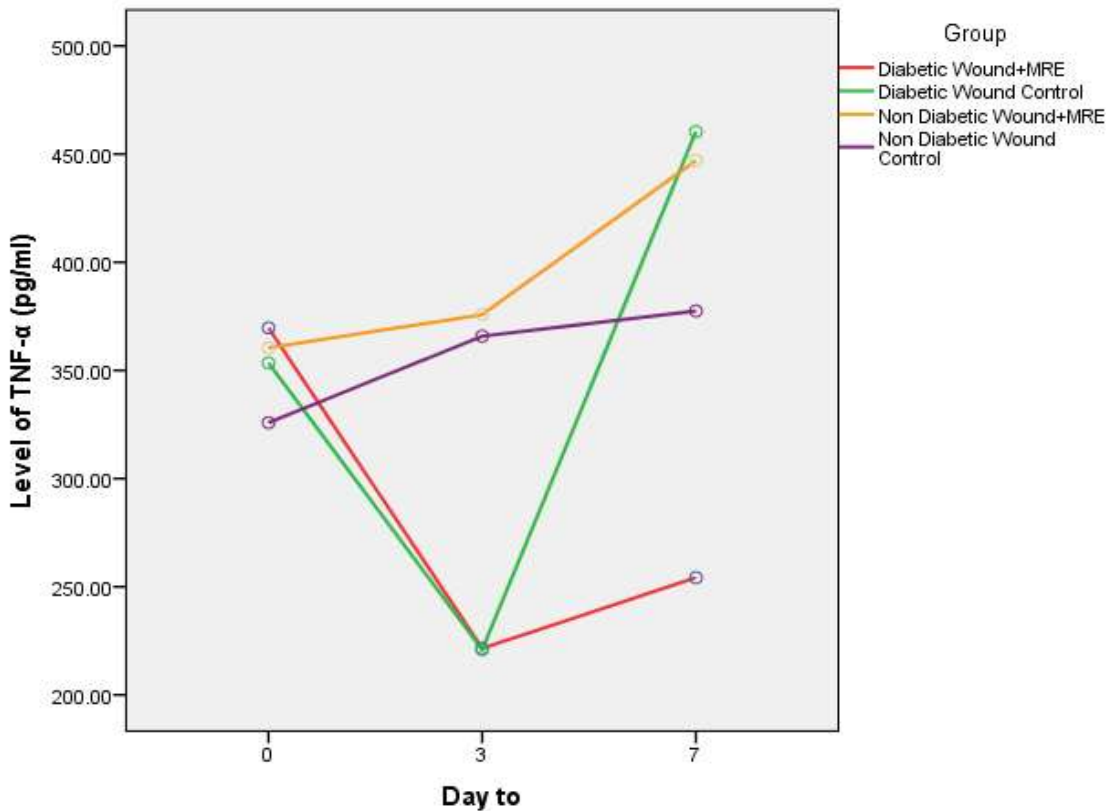


**Figure 1.** Animal Blood Glucose Level on Diabetic Wound Healing

Figure 1. indicated animal blood glucose level on diabetic wound healing post tooth extraction before and after administration STZ. Early blood glucose at the time of fasting in diabetic wound group was hyperglycemia ( $\geq 250$  mg/dl). On day 0 after administration of STZ, average blood glucose level in diabetic wound was 406.50 mg/dl (treated MRE) and 317.50 mg/dl (control). Subsequently on day 10 diabetic wound treated MRE decreased significantly (75%, 129.80 mg/dl) as well 50% at day 14 (192.80 mg/dl). While average blood glucose level in diabetic wound control group slightly decrease (10%) on day 10 (278.20 mg/dl) and day 14 (255.40 mg/dl).

TNF- $\alpha$  level on inflammatory phase of diabetic wound healing post tooth extraction was indicated in Figure 2. TNF- $\alpha$  level of diabetic wound treated MRE was only 50% of control group and there was a significant difference between diabetic wound group ( $p < 0.05$ ), TNF- $\alpha$  level decreased 40% in inflammatory phase.





**Figure 2.** Level of TNF- $\alpha$  on Inflammatory Phase of Wound Healing

Figure 2 showed that the level of TNF- $\alpha$  on inflammatory phase (day 0 to 7) of wound healing post tooth extraction. TNF- $\alpha$  level in diabetic wound group had a similar pattern from day 0 to 3 between diabetic wound treated MRE and control but on the 7<sup>th</sup> day the TNF- $\alpha$  level in diabetic wound control was higher 95% than group treated MRE. On the day 0 TNF- $\alpha$  level of those group was range 355 -370 pg/ml, day 3 there was a decrease in TNF- $\alpha$  30% which both TNF- $\alpha$  level in diabetic wound treated MRE and control was 220 pg/ml. On the 7<sup>th</sup> day diabetic wound group had risen which one treated MRE increased 10% (255 pg/ml) and control group 105% (460 pg/ml). Based on Wilcoxon Signed Rank Test, there was a significant difference TNF- $\alpha$  level between diabetic wound group ( $p=0.028$ ). Among non-diabetic wound group, TNF- $\alpha$  level had increased from day 0 to 7, non-diabetic wound treated MRE 25% from 360 pg/ml to 445 pg/ml while in control group 18% from 325 pg/ml to 380 pg/ml.

**B. Discussion**

Acute toxicity test using Balb/C mice for 14 days

with varying doses of each group (5, 50, 300, 2000, 5000 mg/kg BW and control) did not result in toxicity and mortality and safe consumption in accordance with the results Microbiological tests in which there are no bacteria Escherichia coli, Pseudomonas aeruginosa, Salmonella sp, Staphylococcus aureus (20). This result of acute toxicity test was consistent with a study at various doses (1.0, 2.0 and 3.0 g/kg BW) in rat (29) stated that MRE did not produce significant toxic effect in rat during 14 days treatment period related to weight, hematology and organ weight parameters of each internal organ. In this study treatment with MRE was given topically because it aims to achieve local effect, more effective, minimal systemic effect and as a drug delivery primarily as an anti-inflammatory in wound healing process. If MRE is given systemically it will require a higher dose to be secreted substantially in wound post tooth extraction (30).

In this study induction of diabetes in animals attempted to use diabetogenic Streptozotocin (STZ) agent as compared to other agent (Alloxan), Streptozotocin agent was more stable and specific for pancreatic beta cells and did not require high



doses. STZ-induced animal was male Wistar rat with similar status to diabetes in human (31-34). Meanwhile, according to (35) chronic diabetes because STZ induction in rat resembled many human but not all of chronic complication observed in diabetic human. Administration of a single dose of STZ 50 - 65 mg/kg Intraperitoneal, after 8-10 days of blood glucose achievement at fasting time  $\geq$  250 mg/dl, an experimental animal was present in hyperglycemia or diabetes (24-26, 36). Induction of STZ at dose of 50 to 65 mg/kg BW caused hyperglycemia without side effect such as severe ketosis and did not require insulin to survive, if higher dose ( $\geq$  75 mg/kg BW) lead to spontaneous ketosis and death within a few days if insulin was not given (35).

Diabetic agent STZ is most commonly used to induce diabetes in animal model as early microangiopathic lesion, such as basal membrane thickening and pancreatic damage are commonly used to create models of type 1 diabetic mice with diabetic similarity to nephropathy in humans (34). In case of STZ induced diabetes, AGEs (Advanced Glycation End Products) stimulated macrophage to secrete NO (Nitric Oxide), ROS and TNF- $\alpha$ . The accumulation of AGEs, increased oxidative stress and TNF- $\alpha$  was a major factor in occurrence of ND (diabetic neuropathy) (37). In this study, a rat model with type 1 diabetes, fasting blood glucose of male Wistar rats after administration of STZ ranged from 300 to 600 mg/dl. Then on the 10<sup>th</sup> and 14<sup>th</sup> day this level in diabetic group treated MRE decreased (50% - 75%) while in the control group there was a slight decrease (10%). This result was in accordance with research conducted (17) where MRE with a dose of 100 mg/kg BW could reduce blood glucose level in rat.

Process of diabetic wound healing experienced several disorders such as vascularization, inflammatory and angiogenesis responses as well deposit collagen. In condition of hyperglycemia (diabetes), Advanced End Glycation Products (AGEs) result in production and elimination of free radical and oxidative stress in blood vessel involving in vascular disorder decreased oxygen and nutrient (38, 39). Restriction of blood supply, oxygen and nutrient in tissue cause neuropathy, decrease tissue perfusion and affect inhibition of neovascularization (37). Diabetic wounds represent excessive inflammatory reaction increasing level of pro inflammatory cytokine thus suppressing synthesis of Extracellular Matrix Protein (ECM) (14).

It may decrease production of fibroblast, inhibit collagen and granulation tissue formations as well failure of diabetic wound healing. TNF- $\alpha$  as pro inflammatory cytokine that plays a role in blood vessel dilatation by increasing permeability and inflammatory response in inflammatory phase. In this study, mangosteen rind extract was applied topically in diabetic wound tend to prevent free radical in blood vessel and control pro inflammatory cytokine accelerating diabetic wound healing post tooth extraction.

The results of this study showed on day 0 TNF- $\alpha$  level of diabetic wound post tooth extraction was relatively high 350-370 pg/ml and on day level 3 its level tended to fall 40%. Mangosteen rind extract applied topically to diabetic wound post tooth extraction tended to control the TNF- $\alpha$  level until day 7 (inflammation phase) only increased 10% compared with the control group increased by 105%. TNF- $\alpha$  level in diabetic wound control group was twice as high as diabetic wound group treated MRE. At low level, TNF- $\alpha$  could support wound healing indirectly stimulating inflammation and increase growth factor in macrophage production. TNF- $\alpha$  was a major cytokine and played an important role as a mediator of an inflammatory response that had been shown to be involved in bone resorption (40, 41).

However at higher level, especially in long term, TNF- $\alpha$  had an adverse effect on healing process which can suppress synthesis protein matrix extracellular (ECM), as inhibitor of tissue metalloproteinases (TIMPs) and increase synthesis of matrix metalloproteinases (MMPs) (14). Increased activity of MMPs might degrade synthesis protein ECM inhibiting cell migration and collagen deposition as well break down growth factor and target cell receptor (42). Constant inflammation was responsible for delayed formation of granulation tissue and failure of closure in diabetic wound (43). Studies have been done regarding the negative effects of high TNF- $\alpha$  level that were too high in inflammatory phase according to the results of this study where on the 14<sup>th</sup> day clinically seen diabetic wound treated MRE had closed 99% compared to the control group 64%.

## Conclusions

Mangosteen rind extract topically had significantly affect on TNF- $\alpha$  level and accelerated diabetic-type 1 wound healing post tooth extraction in rat. TNF- $\alpha$  level of diabetic wound treated MRE was only 50%



of control group. This mangosteen rind extract tended to reduce 40% TNF- $\alpha$  level on day 3 (initial of inflammation phase) and control its level until the 7<sup>th</sup> day (final of inflammation phase).

## References

- Nathan DM, Davidson MB, DeFronzo RA, Heine RJ, Henry RR, Pratley R. Impaired fasting glucose and impaired glucose tolerance implications for care. *Diabetes care* 2007; 30 (3): 753-759.
- Brem H, Tomic-Canic M. Cellular and molecular basis of wound healing in diabetes. *The Journal of clinical investigation* 2007; 117(5): 1219-22.
- Falanga V. Wound healing and its impairment in the diabetic foot. *The Lancet* 2005; 366(9498): 1736-43.
- Eming SA, Hammerschmidt M, Krieg T, Roers A, editors. Interrelation of immunity and tissue repair or regeneration. Elsevier: Seminars in cell & developmental biology 2009: 517-527.
- Brem H, Tomic-Canic M. Cellular and molecular basis of wound healing in diabetes. *Journal of Clinical Investigation* 2007; 117 (5): 1219.
- Goren I, Müller E, Pfeilschifter J, Frank S. Severely impaired insulin signaling in chronic wounds of diabetic ob/ob mice: a potential role of tumor necrosis factor- $\alpha$ . *The American journal of pathology* 2006; 168 (3): 765-777.
- Galkowska H, Wojewodzka U, Olszewski WL. Chemokines, cytokines, and growth factors in keratinocytes and dermal endothelial cells in the margin of chronic diabetic foot ulcers. *Wound Repair and Regeneration* 2006; 14(5): 558-565.
- Galiano RD, Tepper OM, Pelo CR, Bhatt KA, Callaghan M, Bastidas N, et al. Topical vascular endothelial growth factor accelerates diabetic wound healing through increased angiogenesis and by mobilizing and recruiting bone marrow-derived cells. *The American journal of pathology* 2004; 164(6): 1935-1947.
- Maruyama K, Asai J, Ii M, Thorne T, Losordo DW, D'Amore PA. Decreased macrophage number and activation lead to reduced lymphatic vessel formation and contribute to impaired diabetic wound healing. *The American journal of pathology* 2007; 170 (4): 1178-1191.
- Gibran NS, Jang Y-C, Isik FF, Greenhalgh DG, Muffley LA, Underwood RA. Diminished neuropeptide levels contribute to the impaired cutaneous healing response associated with diabetes mellitus. *Journal of Surgical Research* 2002; 108 (1): 122-128.
- Lobmann R, Ambrosch A, Schultz G, Waldmann K, Schiweck S, Lehnert H. Expression of matrix-metalloproteinases and their inhibitors in the wounds of diabetic and non-diabetic patients. *Diabetologia* 2002; 45 (7): 1011-1016.
- Joe B, Vijaykumar M, Lokesh B. Biological properties of curcumin-cellular and molecular mechanisms of action. *Critical reviews in food science and nutrition* 2004; 44 (2): 97-111.
- Große R, Werner S, Kessler D, Tuckermann J, Huggel K, Durka S. A role for endogenous glucocorticoids in wound repair. *EMBO reports* 2002; 3(6): 575-82.
- Barrientos S, Stojadinovic O, Golinko MS, Brem H, Tomic-Canic M. Growth factors and cytokines in wound healing. *Wound Repair and Regeneration* 2008; 16(5): 585-601.
- Flora R, Mukni M, Girsang BM, Purwanto S. Tumor Necrosis Factor- $\alpha$  sebagai Prediktor Terjadinya Anemia pada Ibu Hamil di Wilayah Endemis Malaria. *Kesmas: National Public Health Journal* 2015; 9(3): 288-292.
- Patel D, Kumar R, Laloo D, Hemalatha S. Natural medicines from plant source used for therapy of diabetes mellitus: An overview of its pharmacological aspects. *Asian Pacific Journal of Tropical Disease* 2012; 2(3): 239-250.
- Pasaribu F, Sitorus P, Bahri S. Uji ekstrak etanol kulit buah manggis (*Garcinia mangostana* L.) terhadap penurunan kadar glukosa darah. *Journal of Pharmaceutics and Pharmacology* 2012; 1(1): 1-8.
- Rassameemasuang S, Sirikulsathean A, Amornchat C, Maungmingsook P, Rojanapanthu P, Gritsanaphan W. Topical application of *Garcinia mangostana* L. pericarp gel as an adjunct to periodontal treatment. *Complementary therapies in medicine* 2008; 16 (5): 262-267.
- Sunarjo L, Hendari R, Sulistijarso N. Kulit Buah Manggis terhadap Kesembuhan Trauma Mekanik pada Rongga Mulut. *Jurnal Riset Kesehatan* 2014; 3(3): 615-621.
- Sunarjo L, Oedijani, Suharti, Susanto HS. The Preliminary Study on Safety of Using Mangosteen Peel Extract as Natural Herbs. *Journal of Medical Science And Clinical Research* 2017; 5(7): 24851-24856.
- Shan T, Ma Q, Guo K, Liu J, Li W, Wang F. Xanthonenes from mangosteen extracts as natural chemopreventive agents: potential anticancer drugs. *Current molecular medicine* 2011; 11(8): 666.
- Şenel S, Hincal AA. Drug permeation enhancement via buccal route: possibilities and limitations. *Journal of Controlled Release* 2001; 72(1): 133-144.
- Nugroho AE. Hewan percobaan diabetes mellitus: patologi dan mekanisme aksi diabetogenik. *Biodiversitas* 2006; 7(4): 378-382.
- Saravanan G, Ponnurugan P, Kumar GPS, Rajarajan T. Antidiabetic properties of S-allyl cysteine, a garlic component on streptozotocin-induced diabetes in rats. *J Appl Biomed* 2009; 7: 151-159.
- Sathishsekar D, Subramanian S. Antioxidant properties of *Momordica Charantia* (bitter melon) seeds on Streptozotocin induced diabetic rats. *Asia Pacific journal of clinical nutrition* 2005; 14 (2): 153-158.
- El-Bahr SM, Taha NM, Korshom MA, Mandour AE-WA, Lebda MA. Influence of Combined Administration of Turmeric and Black Seed on Selected Biochemical Parameters of Diabetic Rats. *Alexandria Journal of Veterinary Sciences* 2014; 41(1): 19-27.
- Gardner SE, Frantz RA, Bergquist S, Shin CD. A prospective study of the pressure ulcer scale for healing (PUSH). *The Journals of Gerontology Series A: Biological Sciences and Medical Sciences* 2005; 60(1): 93-97.
- Joslin JO. Blood collection techniques in exotic small mammals. *Journal of Exotic Pet Medicine* 2009; 18(2): 117-139.
- Vishnu Priya V, Jainu M, Mohan SK, Karthik B, Saraswathi P, Chandra Sada G. Toxicity study of *Garcinia mangostana* Linn. pericarp extract in rats. *Asian J Exp Biol Sci.*, 2010; 1(3): 633-637.



- Li Q, Xu J-G. Effects of Extraction Solvents on Phytochemicals and Antibacterial Activities of *Garcinia mangostana* Pericarp. *Asian Journal of Agricultural and Food Sciences* 2014; 2(4): 289-295.
- Furman BL. Streptozotocin-induced diabetic models in mice and rats. *Current Protocols in Pharmacology* 2015; 5(47): 1-5.
- Goyal SN, Reddy NM, Patil KR, Nakhate KT, Ojha S, Patil CR. Challenges and issues with streptozotocin-induced diabetes—A clinically relevant animal model to understand the diabetes pathogenesis and evaluate therapeutics. *Chemico-biological interactions* 2016; 244: 49-63.
- Lenzen S. The mechanisms of alloxan-and streptozotocin-induced diabetes. *Diabetologia* 2008; 51(2): 216-226.
- Tesch GH, Allen TJ. Rodent models of streptozotocin-induced diabetic nephropathy (Methods in Renal Research). *Nephrology* 2007; 12(3): 261-266.
- Wei M, Ong L, Smith MT, Ross FB, Schmid K, Hoey AJ, et al. The streptozotocin-diabetic rat as a model of the chronic complications of human diabetes. *Heart Lung & Circulation* 2003; 12(1): 44-50.
- Okyar A, Can A, Akev N, Baktir G, Sütülpinar N. Effect of Aloe vera leaves on blood glucose level in type I and type II diabetic rat models. *Phytotherapy research* 2001; 15(2):157-161.
- Chow FY, Nikolic-Paterson DJ, Atkins RC, Tesch GH. Macrophages in streptozotocin-induced diabetic nephropathy: potential role in renal fibrosis. *Nephrology Dialysis Transplantation* 2004; 19(12): 2987-2996.
- Giacco F, Brownlee M. Oxidative stress and diabetic complications. *Circulation research* 2010; 107(9): 1058-1070.
- Okada H, Kalluri R. Cellular and molecular pathways that lead to progression and regression of renal fibrogenesis. *Current molecular medicine* 2005; 5(5): 467-474.
- Brezniak N, Wasserstein A. Orthodontically induced inflammatory root resorption. Part I: the basic science aspects. *The Angle orthodontist* 2002; 72(2): 175-179.
- Jäger A, Zhang D, Kawarizadeh A, Tolba R, Braumann B, Lossdörfer S, et al. Soluble cytokine receptor treatment in experimental orthodontic tooth movement in the rat. *The European Journal of Orthodontics* 2005; 27(1): 1-11.
- Mast BA, Schultz GS. Interactions of cytokines, growth factors, and proteases in acute and chronic wounds. *Wound Repair and Regeneration* 1996; 4(4): 411-420.
- Wetzler C, Kämpfer H, Stallmeyer B, Pfeilschifter J, Frank S. Large and sustained induction of chemokines during impaired wound healing in the genetically diabetic mouse: prolonged persistence of neutrophils and macrophages during the late phase of repair. *Journal of investigative dermatology* 2000; 115(2): 245-253.

