



Gum Arabic's Effect on Carboplatin-Induced Hepatotoxicity in Male Rats

Marwah A. Alshorbaji

Banan R. Dabdoub

marwah.20esp35@student.uomosul.edu.iq banandabdoub@uomosul.edu.iq

Biology department, Education College for pure Sciences University of Mosul-Iraq

ABSTRACT

Our study showed the therapeutic effect of Gum Arabic(15%) on male rats after being injected with carboplatin(50mg/kg), Which is used to treat cancer and has serious side effects on cancer patients, including hepatotoxicity and oxidative stress. Our results showed the group was injected with carboplatin abnormalities in liver function and an increase in the percentage of liver enzymes such as the alanine aminotransferase, the aspartate aminotransferase, Alkaline phosphatase, and Gamma-glutamyl transferase in the blood, in addition to a decrease in antioxidants such as Catalase and Glutathione and an increase in the Lipid peroxide in the liver tissue. As for the group treated with Gum Arabic after being injected with carboplatin, there were few statistically significant differences when compared with the control group; the Gum Arabic reduced the hepatotoxicity induced by carboplatin and the level of liver enzymes in the blood to The normal level, as well as lipid peroxidation, increased the percentage of antioxidants in the tissues. The reason is due to the properties of Gum Arabic, as it is considered a free radical scavenger, antioxidant, and anti-inflammatory, and is used as a treatment in alternative medicine.Our study aims to reduce the hepatotoxicity induced by carboplatin in male rats using herbal medicine (Gum Arabic). It preserved the liver from oxidative stress and protected the liver from damage.

2547

Keywords

Acacia senega, Cancer, Herbal medications, liver toxicity, platinum drug, oxidative stress

DOI Number: 10.14704/nq.2022.20.8.NQ22275

NeuroQuantology 2022; 20(8):2547-2556

INTRODUCTION

Carboplatin is chemotherapy used to treat types of cancer such as lung, ovarian, endometrial, uterine, bladder, bone marrow suppression, and nervous system tumors. Continuing to receive chemotherapy in high doses due to severe damage that affects the functions of human body organs(HASSAN et al., 2019). Most cancer drugs generate lipid peroxide and free radicals that attack the cells of the body, which causes oxidative stress, which affects the life cycle of the cell, causes

checkpoint stops, and which may reduce the effectiveness of anticancer drugs and kill cancer cells(Yousef et al., 2009).

The liver is an essential organ in the body that maintains homeostasis and carries out biological processes, and has a role in metabolism, secretion, and storage processes, as well as working to detoxify drugs and chemicals from the body. Liver disorders may lead to cirrhosis, fibrosis, and apoptosis(Adewusi and Afolayan, 2010). The generation of free radicals causes liver damage,



lipid peroxidation, and hepatocyte apoptosis (Dabdoub et al., 2020; Kasem, 2019).

Antioxidant supplements are used during chemotherapy to reduce toxic side effects, helping patients tolerate chemotherapy and its effects (Fuchs-Tarlovsky, 2013). The hepatotoxicity caused by carboplatin results from forming free radicals and the deficiency of antioxidants. Medicinal plants are considered a natural source of antioxidants, and they are used as a treatment alternative to medication (Kasem, 2019).

Gum Arabic *Acacia senega* (G.A.) is one of the ancient medicinal plants. It is a solid knot formed on twigs and stems in dry Gum. It is non-sticky, soluble, and rich in fiber. It is extracted from the genus *Senegalia* and the family Fabaceae. It is abundant in Sudan, where it is used in the pharmaceutical industries and is used as a preservative. It has antioxidant, anti-inflammatory, and anti-obesity properties (Jaafar, 2019). and plays a preventive and curative role in improving liver, kidney, and heart functions and preventing histological changes. As interest in Gum Arabic increases, it is used as an antioxidant agent to reduce oxidative damage (Ayaz et al., 2017; Kassem and Abdullah, 2015).

This study was conducted to discover Gum Arabic's therapeutic effect and its role in reducing hepatotoxicity caused by carboplatin and reducing oxidative damage in male albino rats.

Material and method

Chemicals

Carboplatin was obtained from Glenmark Pharmaceuticals Limited Medicinal product authorized by the Argentine Ministry of Health (www.glenmark-generics.com). In a vial, rats injected with a single dose of 50 mg/kg intraperitoneally. (Thews et al., 2001). Gum Arabic was obtained from the local market of

Mosul, Iraq. It was ground into a powder and dissolved in warm distilled water with a concentration of 15%. It was prepared daily and given to rats with drinking water (Nemmar et al., 2019).

Experimental animals

Twenty-four male albino rats (250±50) g at three months old were obtained from the animal house, College of Veterinary Medicine, University of Mosul, Iraq. The rats were kept in specialized cages at a temperature of (23±3 C°). They were given a normal diet, healthy water, illumination of 12:12 hours, and Light and darkness. They were divided into four groups; they were left for two weeks to acclimatize the animals to each other

Experimental design

After two weeks of acclimation, before starting the experiment. Animals were divided into four equal groups (6 animals in each group) and treated as follows: the first group (control) rats were injected intraperitoneally (i.p) with normal saline (0.9% NaCl) once. The second group was treated orally for 30 consecutive days with Gum Arabic (15%, w/v) in drinking water. The third group was treated with a single injected intraperitoneally (i.p) carboplatin dose of 50 mg/kg. The fourth group was treated with a single dose of carboplatin (50mg/kg) i.p after 48 hours and given GA (15%) in drinking water for 30 days. At the end of the scheduled 30th day of the experiment, all the animals were sacrificed

Sampling

Blood and Tissue sampling

After the animal was sacrificed, the blood was collected from the heart and placed in test tubes to separate the serum for Biochemical analysis. After collecting the blood, the liver was collected and washed to get rid of the remnants of the blood and dried, and a part of it was taken to make the tissue sections, and the rest



was kept at -20 temperature until the biochemical tests were done.

Biochemical analysis

Liver function tests

Use the serum to measure the concentration of aspartate aminotransferase(AST), and The alanine aminotransferase(ALT) was estimated using a DiaSys respons 920 – (Diagnostic Systems GmbH). The concentration of Gamma-glutamyl Transferase, Alkaline phosphatase was measured using a device DRI-CHEM NX500 (Product: FUJI DRI-CHEM NX500/FUJI DRI-CHEM NX500i)

Assessments of oxidative stress

Liver tissues were cut, weighed, and a homogenizer was used to obtain a physiological solution and to perform oxidative stress tests. The level of catalase(CAT), glutathione(GSH), and malondialdehyde(MDA) in liver tissues, was measured using the manual method, according to the(Hadwan, 2016; Moron et al., 1979; Volken et al., 2001) Respectively.

Histological section preparation of liver

After collecting the liver samples, they were washed to get rid of the blood, then placed in

formalin at a concentration of 10%, then treated with increasing concentrations of alcohol, purified with xylol, embedded with paraffin, and cut 4 µm thick, then stained with Hematoxylin and Eosin dye.

Statistical Analysis:

The ANOVA test was performed to analyze the results in Graph Prism Software V. 7.00, and statistical significance was defined as p< 0.05.

RESULTS

During the experiment, which lasted 30 days, there were no deaths. Table (1) shows statistically significant differences, Noted that in the group injected with carboplatin (50mg/kg), the percentage of AST, ALT, ALP, and GGT increased significantly compared to the control group.

As for the group that was treated with G.A. after being injected with carboplatin (50mg/kg), noted that there were significant differences with the group that was injected with carboplatin, and if compared with the control group, it indicated that there are no significant differences for ALT and GGT, but there are few significant differences for AST and ALP.

Table (1) The liver function parameters The alanine aminotransferase, aspartate aminotransferase, Alkaline phosphatase, and Gamma-glutamyl Transferase for all groups

2549

Group\parameters	The alanine aminotransferaseU /L	aspartate aminotransferase U/L	Alkaline phosphatase U/L	Gamma-glutamyl Transferase U/L
control	42.82± 2.729	131.4± 9.032	379.7± 46.06	2.667± 0.516
GA	37.90± 3.674	134.0± 15.33	447.5± 146.8	1.667± 0.816
Carboplatin (50 mg/kg)	82.20± 3.617***	184.7± 9.07***	634.4± 38.56***	20.12± 2.164***
Carboplatin (50 mg/kg)+ GA	51.55± 10.89	153± 11.85*	561.7± 29.50**	1.500± 0.837



Values are expressed as mean \pm SD (n=6). *, **, and *** Significant at P < 0.05 indicate in comparisons concerning the control group

Table (2) shows that the antioxidants for the liver in the group injected with carboplatin showed significant differences compared to the control group, Noting a significant decrease in the antioxidants GSH and CAT and a high percentage of fat peroxide MDA. After being

injected with carboplatin, the fourth group treated with Gum Arabic noted a decrease in lipid peroxide and an increased percentage of the antioxidants GSH and CAT.

2550

Table (2) liver oxidative stress parameters (MDA - GSH - CAT) for all groups

Group\parameters	malondialdehyde nmol/gm	Glutathione (μ mol/gm)	Catalase kU/gm
control	351.1 \pm 15.56	5.036 \pm 0.391	403.5 \pm 44.06
GA	326.6 \pm 13.57	4.861 \pm 0.360	435.8 \pm 44.62
Carboplatin (50 mg/kg)	541.6 \pm 16.69***	2.958 \pm 0.391***	153.9 \pm 43.00***
Carboplatin (50 mg/kg) + GA	383.8 \pm 19.45*	3.821 \pm 0.230*	332.6 \pm 41.18*

Values are expressed as mean \pm SD (n=6). *, **, and *** Significant at P < 0.05 indicate in comparisons concerning the control group



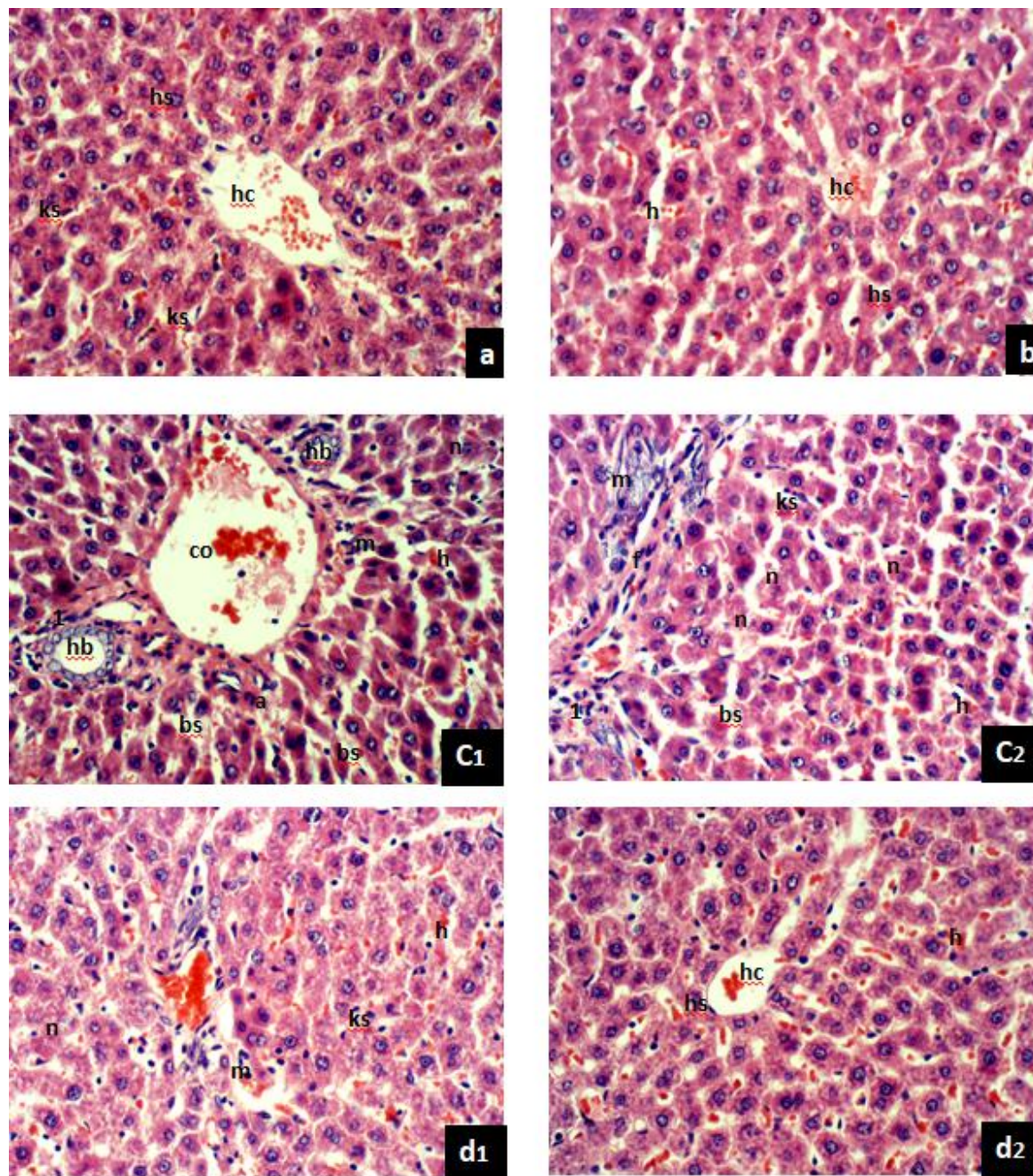


Figure (1) shows the histological sections of the liver (400X)(H&E) :
(a) the control group showed normal hepatocytes (hs), a few Kupffer cells (ks), and hepatic cords (hc) that surround the central vein



(b) Gum Arabic group: There is no difference with the control group, where noted normal hepatocytes (hs) around the hepatic cords (hc) and the hepatocytes (hs) are naturally and noted a slight hemorrhage (h).

(c1,2) Carboplatin 50mg/kg: Note in the figure distension of blood vessels, Hypertrophy of Bile canaliculi (H.B.) in the Portal Area, and expansion of the blood sinusoids (bs). Noted the infiltration of mononuclear inflammatory cells (m), necrosis (n), and apoptosis (a), as well as hemorrhage (h) and slight congestion (co), fibrosis (f), bleeding (h), and expansion of the blood sinusoids (bs), kupffer cells (ks).

Discussion

The most prominent side effect of platinum drugs is hepatotoxicity, which depends on the dose ratio. Carboplatin is administered by intraperitoneal injection or intravenously in the rats (HASSAN et al., 2019).

The first table shows an increase in the liver AST and ALT in the third group that was treated with carboplatin (50mg/kg) compared to the control group; where these enzymes are found at low levels in the blood, these enzymes are produced in the liver cells and stored inside the cytoplasm of the cells. When any damage occurs to the liver cells, these enzymes are leaked into the blood, and their rate increases (Kasem, 2019; Yousef et al., 2009).

As well as an increase in a ALP and GGT, these enzymes are secreted in the liver by the cells lining the bile, and any defect that affects the liver cells affects its secretion, and the rate of its synthesis in the cells increases. Resulted in a defect in the cell receptors and the permeability of the membrane, so its percentage in the blood increases, which is evidence of liver injury (Kim et al., 2004).

(d1,2) Carboplatin 50mg/kg +gum Arabic: noted the normal arrangement of hepatocytes (hs) in hepatic cords (hc) around the central vein, a few infiltrations of inflammatory cells (m), a few numbers of Kupffer cells (ks), a few fibrosis rate (f), and a few expansion of the blood sinusoids (bs), a few hemorrhages (h) between cells. In addition, noted changes in the tissue sections were treated with carboplatin 50mg/kg (c1,2). As for the tissue sections treated with Gum Arabic (d1,2), noted a decrease in tissue damage and the return of the tissue to normal, but it did not reach the control group.

Carboplatin causes damage to liver cells as a result of platinum deposition in their cells as well as oxidative stress that damages the body cell, especially the liver, changing their shape and causing death, protein damage, and their expansion into the sinus space and also induces hepatic hemorrhage and apoptosis by activating caspase-3, releasing cytochrome C, and affecting the cell's DNA (Yousef et al., 2019).

Therefore, the current study used Gum Arabic as an antioxidant and anti-inflammatory agent that prevents the formation of free radicals or reduces its harmful effects induced by carboplatin. The fourth group, which was treated with Gum Arabic, noticed a decrease in the level of ALT, AST, GGT, and ALP. Still, it did not reach the normal level, indicating that Gum Arabic reduces liver damage by free radical scavenging properties and can be used as a preventive agent. These results agree with (Hussein and Mohammed, 2021; Kassem and Abdullah, 2015).

In the second table, an increase in the percentage of MDA and a decrease in the antioxidants GSH and CAT in the third group if



compared to the control group (Al-Kenanny et al., 2012; ElGendy and Elsaed, 2019).

Carboplatin causes oxidative stress and produces different "reactive oxygen species ROS" such as superoxide anion radical (O_2^-), hydrogen peroxide (H_2O_2), and hydroxyl radical ($\bullet O.H.$). That cause oxidative damage to the cell body, especially hepatocytes cause liver injury; they can damage proteins, lipids, carbohydrates, etc., and inhibit the enzymes of the antioxidants CAT and GSH. Several antioxidants have been used to reduce free radicals or reduce the side effects of carboplatin. The action of antioxidants is either donating hydrogen or scavenging free radicals, giving an ion to superoxide and hydroxyl (Hadwan, 2016; Zhong et al., 2020).

Carboplatin injections in a single dose cause the generation of free radicals such as superoxide anion, hydrogen peroxide, and hydroxyl radicals, which increase the level of MDA in the liver. These radicals bind strongly to the hydrogen ion, working to remove it from the unsaturated fatty acids present in the cell membrane where lipid peroxide is generated. It causes cell permeability defects (ElGendy and Elsaed, 2019).

Glutathione is one of the antioxidants, as it inhibits the action of free radicals, as it is oxidized by the enzyme GSH-PX and the formation of glutathione disulfide GSSG. The latter is reduced by the enzyme GSH-SR to GSH in the presence of NADPH produced by glycolysis. An increase of free radicals prevents the conversion of GSSG to GSH due to a lack of hydrogen ions, thus increasing the proportion of GSSG and decreasing GSH and accumulation

of free radicals, thus causing liver injury and the percentage of MDA increases (Dabdoub, 2021).

Catalase is an enzyme secreted in the liver that protects cells from reactive oxygen species. It breaks down hydrogen peroxide, which is toxic to cells, and destroys proteins and fats. The enzyme breaks down hydrogen peroxide into water and oxygen, thus eliminating its toxic effect on cells and reducing the free radical (ElGendy and Elsaed, 2019; Hadwan, 2016).

In addition, increase in Kupffer cells in the third group due to liver injury. It is macrophages, that maintain liver cells, as they rid the liver of pathological and foreign bodies, increase when inflammation, steatosis, and fibrosis occur in the liver. as they are the first line of defense against bacteria and endotoxins, as well as remove dead cells and aging red blood cells; during the work of Kupffer cells, they secrete cytokines as well as free radicals, especially nitric oxides (Tacke, 2017).

When Compared to the fourth group, which was treated with G.A. after being injected with carboplatin (50mg/kg) with the control group, with a significant increase in antioxidants and a decrease in MDA, Gum Arabic is a natural substance and easily soluble in water because it has a protein part that is covalently linked to carbohydrate polymers, as well as it can remove free radicals acts as an antioxidant by inhibiting free radicals because it has the property of free radical scavenging (Hassani et al., 2020; Hussein and Mohammed, 2021). it contains antioxidant compounds such as phenolic acids, flavonoids, and phenolic diterpenes. It has been proven that flavonoids oxidize easily, thus reducing free



radicals (Kaddam et al., 2017). And it also can decrease inflammatory cytokines (Ali et al., 2013). Nitric oxide is considered a free radical because it contains a non-double number of electrons, so it is unstable and tends strongly to bond. It causes physiological and histological changes to cells. Gum Arabic is a free radical scavenger, especially NO metabolism, as it turns into nitrates and nitrites and reduces the effect of Kupffer cells, thus preserving liver cells by reducing the toxicity of free radicals that affect the proteins, lipids, and DNA of hepatocytes (Ayaz et al., 2017; Tacke, 2017).

Our results show that Gum Arabic significantly reduces free radicals, thus increasing the antioxidants CAT and GSH, which protect cells from oxidative stress and significantly reduce MDA, as well as preserving hepatocytes and preventing biomolecules such as fats, proteins, sugars, and DNA damage, thus reducing liver enzymes such as ALT, AST, ALP, and GGT, where G.A. preserved liver cells from apoptosis.

Conclusion

Medicinal herbs can be used as an effective treatment for the treatment of hepatotoxicity resulting from anticancer drugs. Gum arabic helped reduce carboplatin-induced hepatotoxicity in rats because it is an antioxidant and anti-inflammatory, reduced MDA, and increased antioxidants. After all, it is effective in scavenging free radicals, thus reducing hepatotoxicity. Therefore, we recommend that more research on Gum arabic and its use to reduce the side effects of treating cancer patients

Acknowledgment

I want to express my sincere thanks to the Dean of the College of Education for Pure Sciences and the Dean of the College of Veterinary Medicine. The University of Mosul-Iraq for their efforts to assist in completing scientific research.

Abbreviations

GA	Gum Arabic (Acacia senega)
GGT	Gamma-glutamyl Transferase
ALT	The alanine aminotransferase
AST	The aspartate aminotransferase
ALP	Alkaline phosphatase
MDA	Malondialdehyde
GSH	Glutathione
CAT	Catalyzes
i.p	intraperitoneal

Reference:

- Adewusi, E., and A.J. Afolayan. 2010. A review of natural products with hepatoprotective activity. *Journal of Medicinal Plants Research*. 4:1318-1334.
- Al-Kenanny, E., L. Al-Hayaly, and A. Al-Badrany. 2012. Arabic Gum's protective effect of arabic Gum on liver injury is experimentally induced by gentamycin in mice. *مجلة الكوفة للعلوم البيطرية / Kufa Journal For Veterinary Medical Sciences*. 3.
- Ali, B.H., I. Al-Husseni, S. Beegam, A. Al-Shukaili, A. Nemmar, S. Schierling, N. Queisser, and N. Schupp. 2013. Effect of Gum arabic on oxidative stress and inflammation in adenine-induced chronic renal failure in rats. *PLoS one*. 8:e55242.



- Ayaz, N.O., K.S. Ramadan, H.E. Farid, and H.S. Alnahdi. 2017. Protective role and antioxidant activity of Arabic Gum against trichloroacetate-induced toxicity in the liver of male rats. *Indian Journal of Animal Research*. 51:303-309.
- Dabdoub, B.R. 2021. The Role of Vitamin D3 as an Antioxidant and Hepatic Treatment against the Toxic Effect of Cadmium Chloride in The Rats. *Indian Journal of Forensic Medicine & Toxicology*. 15.
- Dabdoub, B.R., R.H. Mohammed, and H.L. Abdulhadi. 2020. Ganoderma lucidum attenuates and prevents CCl4-induced hepatic and renal damage in Sprague–Dawley Rats. *Systematic Reviews in Pharmacy*. 11:1704-1709.
- ElGendy, A.A., and W.M. Elsaed. 2019. The Role of Erythropoietin, Vitamin C and L-NAME in Carboplatin-Induced Hematological and Renal Dysfunctions. *Bulletin of Egyptian Society for Physiological Sciences*. 39:231-251.
- Fuchs-Tarkovsky, V. 2013. Role of antioxidants in cancer therapy. *Nutrition*. 29:15-21.
- Hadwin, M.H. 2016. New method for assessment of serum catalase activity. *Indian Journal of Science and Technology*. 9:1-5.
- HASSAN, E.S., S.A. MAJEED, A.R. MOHAMMAD, and K.K. GAEN. 2019. The protective effect of the N acetylcysteine on acute liver toxicity induced by carboplatin in rat model. *International Journal of Pharmaceutical Research*. 11.
- Hassani, A., M.M.S. Azarian, W.N. Ibrahim, and S.A. Hussain. 2020. Preparation, characterization and therapeutic properties of Gum arabic-stabilized gallic acid nanoparticles. *Scientific Reports*. 10:1-18.
- Hussein, E.A., and H.Q. Mohammed. 2021. Therapeutic Effect of Gum Arabic on some Biochemical Parameters in Nephrotoxic Albino rats. *Indian Journal of Forensic Medicine & Toxicology*. 15:2297.
- Jaafar, N.S. 2019. Clinical effects of Arabic Gum (Acacia): A mini review. *Iraqi Journal of Pharmaceutical Sciences (P-ISSN: 1683-3597, E-ISSN: 2521-3512)*. 28:9-16.
- Kaddam, L., I. Fadl-Elmula, O.A. Eisawi, H.A. Abdelrazig, M.A. Salih, F. Lang, and A.M. Saeed. 2017. Gum Arabic as novel antioxidant agent in sickle cell anemia, phase II trial. *BMC hematology*. 17:1-6.
- Kasem, N. 2019. Ameliorative Effects of Annona muricata (Graviola) and Fullerene C60 Against Toxicity Induced by Carboplatin in Male Albino Rats. *Egyptian Academic Journal of Biological Sciences. C, Physiology and Molecular Biology*. 11:149-168.
- Kassem, A., and A. Abdullah. 2015. Dietary Gum Arabic supplementation alter plasma and tissue antioxidant and free radical scavenging activities in Sprague Dawley Male Rats. *Journal of Biology and Life Sciences*. 6:129.
- Kim, S.H., K.O. Hong, W.-Y. Chung, J.K. Hwang, and K.-K. Park. 2004. Abrogation of cisplatin-induced hepatotoxicity in mice by xanthorrhizol is related to its effect on the regulation of gene transcription.



- Toxicology and Applied Pharmacology*. 196:346-355.
- Moron, M.S., J.W. Depierre, and B. Mannervik. 1979. Levels of glutathione, glutathione reductase and glutathione S-transferase activities in rat lung and liver. *Biochimica et biophysica acta (BBA)-general subjects*. 582:67-78.
- Nemmar, A., S. Al-Salam, S. Beegam, P. Yuvaraju, and B.H. Ali. 2019. Waterpipe smoke exposure triggers lung injury and functional decline in mice: protective effect of Gum Arabic. *Oxidative medicine and cellular longevity*. 2019.
- Tacke, F. 2017. Targeting hepatic macrophages to treat liver diseases. *Journal of hepatology*. 66:1300-1312.
- Thews, O., D.K. Kelleher, and P. Vaupel. 2001. Erythropoietin restores the anemia-induced reduction in cyclophosphamide cytotoxicity in rat tumors. *Cancer Research*. 61:1358-1361.
- Volken, E., G. Nurperi, and B. Ahmet. 2001. N-acetyl cystine reduces cerebral lipid peroxidation in a rat model of infantile hydrocephalus. *J Neurol Sci*.
- Yousef, M., A. Saad, and L. El-Shennawy. 2009. Protective effect of grape seed proanthocyanidin extract against oxidative stress induced by cisplatin in rats. *Food and Chemical Toxicology*. 47:1176-1183.
- Yousef, M.I., M. Mahdy, and H.M. Abdou. 2019. The potential protective role of grape seed proanthocyanidin extract against the mixture of carboplatin and thalidomide-induced hepatotoxicity and cardiotoxicity in male rats. *Preventive Medicine*. 2:1-7.
- Zhong, X., X. Wang, L. Cheng, Y.a. Tang, G. Zhan, F. Gong, R. Zhang, J. Hu, Z. Liu, and X. Yang. 2020. GSH-depleted PtCu₃ nanocages for chemodynamic-enhanced sonodynamic cancer therapy. *Advanced Functional Materials*. 30:1907954.

