



# Factors related to the success and failure of Coronary Total Occlusion Percutaneous Coronary Intervention

2617

Khaled Mohamed M. Mandour\*, Mahmoud Diaa El Menshawy,  
Ahmed Mohamed El Zaiat, Alaa Elsayed Mohamed Salama

## Abstract

**Background:** CTO PCI can provide significant clinical benefits, yet there is limited information on its success and safety in unselected patient populations

**Objectives:** The aim of this study was to describe contemporary frequency, predictors, and outcomes of chronic total occlusion (CTO) percutaneous coronary intervention (PCI).

**Conclusions:** CTO PCI is currently performed infrequently in Egypt for stable coronary artery disease and is associated with lower procedural success and higher complication rates compared with non-CTO PCI. Procedural success was associated with several patient factors and operator experience.

**Key Words:** coronary occlusion, chronic disease, percutaneous coronary intervention.

**DOI Number:** 10.14704/NQ.2022.20.12.NQ77253

**NeuroQuantology 2022; 20(12): 2617-2620**

## Clinical predictors:

### 1- Duration of occlusion:

Several past studies have reported that duration of occlusion make the procedural failure predictable. These authors suggested that a more significant lesion organization with deposition of fibrous tissue, occurring in the course of time from occlusion, might lead to a lower possibility of recanalization. Indeterminate duration of occlusion was a predictor of procedural failure (1).

### 2- Previous attempt:

Previous failed attempt of CTO revascularization has been considered a predictor of failure for a new approach. However, in case of a second approach, several factors should be taken into the right consideration regarding the experience of the operator at the first attempt, the feasibility of different approaches and techniques, the availability of dedicated materials and devices. Furthermore, before the re-attempt, it seems to be advisable to deepen the diagnostic information with other imaging technique such as coronary computed tomography. Previous dissection or perforations created during the first attempt might also heal in few months and a new collateral circulation might develop, enabling to choose a different strategy of approach and affecting the procedural outcome (2).

**Corresponding author:** Khaled Mohamed M. Mandour

**Tel:** (+20)01222253651

**E-mail:** kh.mandour22@medicine.zu.edu.eg

## Affiliations:

Department of Cardiology, Faculty of Medicine- Zagazig University, Zagazig, Egypt

## Relevant conflicts of interest/financial disclosures:

The authors declare that the research was conducted in the absence of any commercial or financial relationships that could be construed as a potential conflict of interest.



### 3- Expected patient tolerance and Co-morbidities:

The tolerance of patients is essential to achieve the procedural success. CTO revascularization requires long time procedure and the patients must lie on supine position for hours and hours. Presence of associated co-morbidities such as musculo-skeletal pain, psychiatric disorders, cardiac or respiratory failure limits the patient ability to lie flat for prolonged periods, especially in older patients. Therefore, a mild sedation is advisable in these cases when a long-lasting procedure is expected (3).

#### Angiographic predictors:

To recanalize a CTO three different steps should be considered:

- a) Penetration of the proximal fibrous cap.
- b) Traversing of CTO body.
- c) Penetration of the distal fibrous cap reaching distal true lumen.

Regarding the proximal fibrous cap, the most important characteristic to consider are represented by:

- Shape of cap
- Presence of side branch
- Grade and type of calcifications at the occlusion entry point (4).

The shape of the cap can be convex (blunt) or tapered (funnel); the first one is an unfavorable factor (especially with associated severe calcifications) because, in such a case, the tip of guide wire might slide off easily in subintimal space when engaging the lesion with higher risk of proximal vessel dissection. Conversely, in presence of tapered stump it is easier to direct the guidewire into the correct entry point of CTO.

The most important angiographic findings in body of occlusion are represented by:

- The length of the occluded segment
- Calcifications and path of the vessel. (4)

Sometimes in the body of occlusion, especially in long duration CTOs, bridge collaterals could give the false impression of a functional occlusion with antegrade micro channels. In these cases, other orthogonal projections are needed to obtain an angiographic differential diagnosis with antegrade microchannels. The presence of this type of collaterals is generally associated with high grade of calcifications and for this reason it is considered to be as an unfavorable

factor (4).

*Regarding the distal cap of the occlusion, we should consider:*

- The shape of the cap
- The presence of calcifications at the exit of occlusion. Distal cap is usually considered less resistant than the proximal cap favoring the newly retrograde approaches. In case of tapered distal shape, the gaining of the guide wire in true lumen is more difficult than convex distal shape.

In case of blunt distal cap, the wire often fails to penetrate and crossing it into the distal true lumen, but instead slides along it into the subintimal space. In addition, block calcifications at the distal cap can deflect the guidewire tip causing severe dissections. It is important then to compare the position of the wire tip with the distal true lumen in different views, as a subintimal location of the wire tip can be missed in some angiographic views (5).

#### Coronary CTO location:

The site of occlusion is an important finding which predict recanalization success rate. Indeed, the occlusion can be located at the ostium, proximal, mid and at the distal part of coronary artery. Ostial location has been considered as an important unfavorable factor rather than other sites (proximal or mid) due to the low guiding catheter support achievable when employing standard techniques. However, very distal CTO location might also be considered unfavorable in some cases, due to poor maneuverability of guide wires especially in case long dissection and calcifications are observed (6).

#### Small vessel size:

The consensus document from Euro CTO club defines complex such a CTO with vessel diameter size less than 3 mm. When the vessel shows a small caliber, the guidewire might slip easily into the adventitia with high risk of coronary perforation. In addition, the long-term outcome of angioplasty in small vessel disease is associated with a higher rate of restenosis and re-occlusion. Moreover, even in presence of proximal vessel size more than 3 mm in diameter, negative remodeling phenomenon might occur in the occluded segment decreasing the likelihood of successful revascularization (6).

#### Tortuosity of the vessel proximal to occlusion:

Severe proximal vessel angulation before CTO location (one bend > 150° or two bends >90°) determines loss of push ability, trackability and steerability of the guidewire and support devices



(microcatheter and OTW balloon) lowering maneuverability and penetration skill of the stiffest guidewire. Also, tortuosity at the site of the occluded segment may be very cumbersome, due to the loss of visualization of vessel path and consequently high-risk probability of dissection when using the penetration wire techniques. According to our experience this is probably one of the most important features for an unfavorable outcome (7).

**Side branch** vessel originating at the proximal cap of a CTO is generally considered an unfavorable factor because the guidewire might be easily deflected by the fibrous cap of the occlusion slipping into the side branch. However, if the side branch is  $\geq$  of 2.0 mm IVUS could be alternatively used increasing success revascularization rate (8).









**Calcifications** are shown by several reports to be predictors of unsuccessful results especially when they are located at the entry point or at distal cap of the occlusion. Moreover, it is very important to consider how calcifications may be shown within the coronary artery. Indeed, calcifications can be observed as blocks or alternatively as patchily distribution within the coronary artery (8).

**Distal vessel disease:**

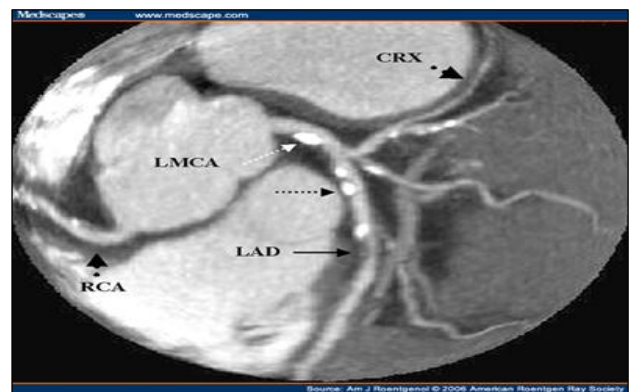In case of proximal-mid occlusion with faint distal opacification, the presence of a distal stenosis to the occlusion cannot be easily assessed. It is quite common the finding of a distal severe lesion or presence of critical disease at bifurcation site which often requires bifurcation reconstruction by two-stent technique. Another important lesion characteristic which might influence the procedural success is the presence of tandem occlusions which are defined as two occlusions in the same segment divided by an island of no disease vessel, therefore, two proximal and distal caps need to be crossed in the setting a CTO (9).

**The role of multi-slice cardiac computed tomography:**

The use of cardiac MSCT in percutaneous revascularization of CTO represents a useful tool: it reveals the coronary ostium position, the CTO length, the collateral circulation path, proximal Tortuosity to the occlusion, Tortuosity of the occluded segment, and vessel size (8).

Predictors of success		Predictors of failure	
Age of occlusion	< 12 weeks	Age of occlusion	> 12 weeks
Length	< 15 mm	Length	> 15 mm
Stump shape		No stump	
Functional occlusion (TIMI I)		Total occlusion (TIMI 0)	
Occlusion distal to sidebranch		Occlusion at level of sidebranch	
No antegrade collaterals		Bridging collaterals	

**Figure (1):** Predictors of success and failure in CTO intervention



**Figure (2):** Coronary CTA

Impact of lesion age on outcomes of chronic total occlusion percutaneous coronary intervention:

**Coronary chronic total occlusions (CTOs)** are defined as 100% occlusions of at least 3-month duration, although it is sometimes challenging to precisely determine the time of the occlusion in the absence of prior coronary angiograms. Older CTOs have traditionally been associated with lower CTO percutaneous coronary intervention (PCI) success rates due to longer lesion length and higher degree of calcification. However, with novel equipment and techniques, success rates of CTO PCI have significantly improved (10).

**Danek et al.** (11) determined the impact of lesion age on procedural techniques and outcomes of chronic total occlusion (CTO) percutaneous coronary intervention (PCI). They concluded that older CTO lesions exhibit angiographic complexity and more frequently necessitate the retrograde approach or antegrade dissection/reentry. Older CTOs can be recanalized with high technical and procedural success rates and acceptable MACE. Lesion age appears unlikely to be a significant determinant of CTO PCI success.



## Conclusion:

CTO PCI is currently performed infrequently in Egypt for stable coronary artery disease and is associated with lower procedural success and higher complication rates compared with non-CTO PCI. Procedural success was associated with several patient factors and operator experience.

2620

## REFERENCES

1. **Barlis P, Kaplan S, Dimopoulos K, Tanigawa J, et al.** An indeterminate occlusion duration predicts procedural failure in the recanalization of coronary chronic total occlusions. *Catheter Cardiovasc Interv* 2008; 71: 621-628.
2. **Di Mario C, Werner S, Sianos G.** European perspective in the recanalization of CTO: Consensus document from the Euro CTO club. *EuroInterv* 2007; 3:30-43
3. **Ivanov J, Osten MD, Eichhofer J.** Impact of renal insufficiency on angiographic , procedural and in-hospital outcomes following PCI. *Am J Cardiol* 2008,101:780-5.
4. **Melchoir JP, Meire B, Urban P.** Percutaneous transluminal coronary angioplasty for chronic total occlusion. *Am J Cardiol* 1987; 59: 535-8.
5. **Kaw D, Malhotra D.** Platelet dysfunction and end-stage renal disease. *Semin Dial* 2006; 19: 317-22.
6. **Morii I, Noguchi T.** PCI of CTO: determinants of primary success and long term outcome. *Cathet Cardiovasc Intervent* 2000,49:258-64.
7. **White RD, Setser RM.** Integrated approach to evaluating coronary artery disease and ischemic heart disease. *Am J Cardiol* 2002; 90: 49L-55L
8. **Apter S, Shemesh J, Rozenman J.** Calcification of coronary arteries. *Radiology* 1995,197:779-83.
9. **Erbel R, Silber S.** Age and gender distribution of coronary artery calcium measured by computed tomography in 2030 person with no symptoms of coronary artery disease. *Am J Cardiol* 2002, 90:168-73.
10. **Irving J.** CTO pathophysiology: how does this affect management? *Curr Cardiol Rev* 2014; 10: 99-107.
11. **Danek BA, Karatasakis A, Karpaliotis D, et al.** Impact of lesion age on outcomes of chronic total occlusion percutaneous coronary intervention: Insights from a contemporary US multicenter registry. *Can J Cardiol* 2016; 32(12): 1433-1439.

