



Oral potentially malignant disorders ,oral cancer and fingerprint patterns : Is there any association?

Dr.Aruneer Garg¹ , Dr.Apurva Garg² , Dr. MK Gupta³

1. Assistant Professor, Dept. of Oral & Maxillofacial Pathology and Microbiology ,Index Institute of Dental Sciences ,Indore, Madhya Pradesh
2. Consultant, Head & Neck Oncosurgeon,Dept of ENT, Choithram Hospital and Research Center,Indore ,Madhya Pradesh
3. Senior Consultant, Oral and Maxillofacial Surgery, SuretechHospital,Nagpur, Maharashtra

Abstract

Background:

Dermatoglyphics play an important role in the identification of a person as well as identifying a person with a genetic abnormality. Hence, the present study was conducted with an aim to explore the association between the fingerprint patterns and oral potentially malignant disorders, oral squamous cell carcinoma (OSCC), individuals with habit and without lesion and the control group.

Materials and Methods:

A cross-sectional study comprising of 100 individuals divided into 5 groups with 20 individuals in each group based on their habit and the presence of oral lesions. Group 1 included individuals with oral leukoplakia (OL), Group 2 included individuals with oral submucous fibrosis (OSMF), Group 3 included individuals who had OSCC, Group 4 individuals had tobacco habits but without lesion and Group 5 comprised of control individuals. The fingerprints of all the study subjects were recorded using a standard ink method. They were analyzed qualitatively and quantitatively.

Results:

The present study showed a predominance of that loop patterns in all the groups. The frequency of the whorled pattern was higher in subjects with OSMF as compared to OL and OSCC. The arch pattern was comparatively lesser in subjects with OL than OSMF subjects. The right-left comparison of the fingerprint patterns in all the five groups, except Group 4, showed a significant association and correlation. The Group 4 individuals were showing the least correlation between sides.

Conclusion:

The study concluded that dermatoglyphics can be used as a potential marker to identify the subjects with risk for potentially malignant oral disorders and oral cancers.

Keywords: Correlation, dermatoglyphics, fingerprint patterns, oral potentially malignant disorders, oral squamous cell carcinoma, right-left association

DOI Number: 10.48047/nq.2021.19.3.NQ21047

NeuroQuantology 2021; 19(3): 1266-1273

INTRODUCTION

Dermatoglyphics was first used in India for personal identification by Herschel.[1] It was

established by Galton in the year 1892.[2] It is defined as a study of the naturally occurring patterns on the surface of the hands and



feet.[3] The development of dermatoglyphic patterns begins with the appearance of fetal pads in the 6th week of gestation and reaches a maximum size between the 12th and 13th weeks while becoming full grown in the 24th week of gestation. From this stage onward, they are largely unaffected by the extraneous factors, and this explains their unique role as an ideal marker for individual identification and the study of populations, as well as in the detection of defects due to intrauterine irregularities in the early stages of gestation.[1] Epidermal ridge remains unchanged from fetal development to throughout of life.[4] The dermatoglyphics is not only used for personal identification but also in human biology for various reasons. It is a well-established fact that tobacco, alcohol abuse and unhealthy lifestyle are the leading causes for the development of oral potentially malignant disorders (PMDs) and oral cancer. Oral PMDs such as oral leukoplakia (OL) and oral submucous fibrosis (OSMF), erythroplakia, lichen planus, sideropenic dysphagia are considered as the precursors of oral squamous cell carcinoma (OSCC).[5] Several factors such as the frequency, duration and type of tobacco habit play a significant role in the initiation and the progression of the PMDs and OSCC. To reduce the burden of oral cancer, it is always mandatory for early detection of tobacco-induced mucosal lesions. There are several methods of early cancer detection available at both institutional and community levels. Similarly, dermatoglyphics also has proved to be a useful adjuvant in predicting the PMDs and OSCC. Earlier studies have shown a strong association of dermatoglyphics with syndromic and genetic diseases.[6] The analysis of fingerprints does not involve sophisticated equipment and it is a noninvasive procedure.[7] Hence, the present study was undertaken to explore the association between the fingerprints and oral PMDs and OSCC and its potential application in the screening of such lesions.

MATERIALS AND METHODS

The present study was carried out on the individuals who attended the outpatient Department of Oral Pathology, Index Institute Of Dental Sciences . The Ethical clearance was obtained from the Institutional Ethical Committee (IEC: IIDS/OP. 6/2021). A total number of 100 individuals were randomly selected using the following inclusion and exclusion criteria. Selection criteria included individuals with a history of tobacco/areca nut chewing for more than 1 year. Exclusion criteria included the presence of oral lesions due to other causes such as sharp tooth margins, improper restorations, prosthesis, alcohol or smoking, patients with scars or any injury to fingers and individuals with any systemic diseases. Study subjects were divided into five groups based on the presence of oral potentially malignant diseases and malignant disease and their habit of tobacco/areca nut intake.

In Group 1: 20 subjects with OL, Group 2: 20 subjects with OSMF, Group 3: 20 subjects with OSCC, Group 4: 20 subjects with a habit of tobacco/areca nut intake without the occurrence of any oral lesions. Group 5: 20 subjects without a history of tobacco/areca nut intake without the occurrence of oral lesions. Groups 1, 2 and 3 were clinically and histopathologically diagnosed. The armamentarium required for the recording of the fingerprints like blue duplicating ink, thick white printing paper (A4 size, 100 g/m²), torch, gauze piece, soap, water and towel. Patients were informed in detail about the study and their informed consent was obtained to conduct the study. A structured format was designed, which consisted of demographic data, detailed history of habits, medical history, family history, clinical examination, diagnosis and histopathology report. Fingerprints were recorded using the "Ink method" by Cummins and Midlo.[7] The ink was uniformly spread on the fingertips of the subjects. Prints of thumbs were taken first, followed by prints of the other fingers. Once acceptable fingerprints were obtained, the subjects were asked to wash their hands. To find the frequency of fingertip print patterns, both hands, i.e., all ten fingers of an

individual were considered together. The viewed patterns were analyzed (qualitatively and quantitatively) according to standard guidelines for classification given by Francis Galton (1982)[7] These patterns are further

subdivided but for simplicity, these three patterns were used for analysis. The three common patterns seen are the arch pattern, the loop pattern and the whorl pattern [Figure 1].




Figure 1
Types of finger print patterns

The data obtained were recorded in the Microsoft Excel spreadsheet and the statistical analysis was performed using SPSS software Statistical Package for the Social Sciences (SPSS) Version 26.0. IBM Corp. Armonk, NY, USA.

RESULTS

On analyzing the data, the loop pattern was found to be the predominant pattern with a frequency of 54.5%–69.5% followed by a whorl pattern with the frequency of 28.5%–42.5% on both sides. The arch pattern was present in only 1%–11% of the cases. The distribution of the arch pattern in Group 4

was significantly different from the arch pattern in all the other groups. Thus, only the arch pattern was showing significant differences between the groups whereas the loop and the whorl patterns were not significantly different among the groups [Table 1]. These findings are also represented in Graph 1. Table 2 shows the frequency distribution of the types of fingerprint patterns in all the fingers. In right and left thumb shows a higher frequency of whorl pattern. Right, and left index finger, middle, ring and little finger shows a higher frequency of loop pattern.

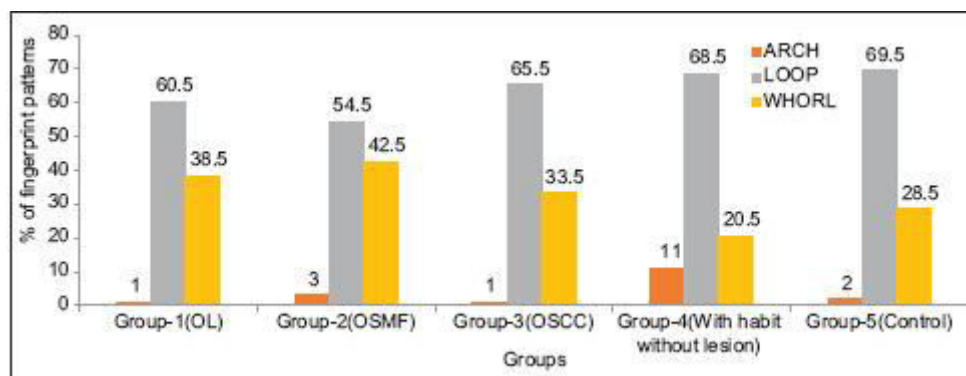
Table 1
The frequency distribution (%) of fingerprint patterns in different study groups

Fingerpr int pattern	Group-1 (n=20), n (%)	Group-2 (n=20), n (%)	Group-3 (n=20), n (%)	Group-4 (n=20), n (%)	Group-5 (n=20), n (%)	Total (n=1000), n(%)	χ^2	d f	P
Arch	2 (1.0)	6 (3.0)	2(1.0)	22 (11.0)	4(2)	36 (3.6)	18.184	4	0.001*
Loop	121 (60.5)	109 (54.5)	131 (65.5)	137 (68.5)	139 (69.5)	637 (63.7)	3.354	4	0.500
Whorl	77(38.5)	85(42.5)	67(33.5)	41(20.5)	57(28.5)	327(32.7)	6.518	4	0.164

*Significant $P < 0.05$

Table 2
The frequency distribution (%) of the types of patterns in all the fingers

Pattern	1. Thumb, n (%)		2. Index, n (%)		3. Middle, n (%)		4. Ring, n (%)		5. Little, n (%)	
	Right	Left	Right	Left	Right	Left	Right	Left	Right	Left
Arch	7(7)	5(5)	10(10)	5(5)	2(2)	5(5)	0	0	0	0
Loop	43 (43)	38 (38)	49 (49)	66 (66)	74 (74)	74 (74)	70 (70)	63 (63)	73 (73)	78 (78)
Whorl	50 (50)	57 (57)	41 (41)	29 (29)	24 (24)	21 (21)	30 (30)	37 (37)	27 (27)	22 (22)



Graph 1

Percent of fingerprint patterns among the different study groups

Whereas the right and left ring and little finger do not show an arch pattern, the right-left comparisons of the fingerprint pattern in all the five groups, except Group 4, showed a significant association and correlation. Group 4 was showing the weakest correlation between sides [Table 3]. The cross-tabulation of the fingerprint pattern in the right- and left-hand fingers revealed a significant association and correlation in Group 1 only in a thumb. In Group 2, highest correlation was seen in the thumb than in the little finger, ring finger, index finger and middle finger, respectively. In Group 3, significant correlation was found in the middle finger, little finger and thumb. In Group 4, significant correlation was found in the little finger and index finger, respectively. Whereas in Group 5, ring finger, little finger, index finger and thumb show significant correlation. Out of which ring finger and little finger in Group 5 show highly significant correlation (0.000) than any other groups [Table 4].



Table 3
 The right and left association and correlation among the different study groups

Group	Right-left association		Right-left correlation	
	Pearson (χ^2)	Significance	Spearman correlation	Significance
1	9.377	0.002*	0.685	0.001*
2	18.693	0.001*	0.706	0.001*
3	7.2	0.007*	0.6	0.005*
4	7.688	0.104	0.443	0.06
5	7.472	0.024*	0.611	0.004*

*Significant at $P < 0.05$

Table 4
 Right and left symmetry pattern among all the study groups fingerwise, Pearson's Chi-square value, and spearman correlation

Group (n=20)	Finger	Right-left symmetry			Total, n (%)	χ^2	Significance	Spearman correlation	Significance
		1=arch	2=loop	3=whorl					
1 (OL)	Thumb	0	6	11	17(85)	9.377	0.002*	0.685	0.001*
	Index	0	10	4	14 (70)	3.300	0.069	0.406	0.076
	Middle	0	9	0	9(45)	2.857	0.582	-0.123	0.604
	Ring	0	7	1	8(40)	1.684	0.194	-0.290	0.215
	Little	0	9	4	13 (65)	2.400	0.121	0.346	0.135
2 (OSMF)	Thumb	2	6	7	13 (65)	18.693	0.001*	0.706	0.001*
	Index	0	6	9	15(75)	7.328	0.026	0.605	0.005*
	Middle	0	11	4	15(75)	4.444	0.035	0.471	0.036
	Ring	0	7	9	16(80)	7.500	0.006	0.612	0.004*
	Little	0	14	3	17(85)	8.235	0.004*	0.642	0.002*
3 (OSCC)	Thumb	0	8	8	16(80)	7.200	0.007	0.600	0.005*
	Index	0	6	5	11 (55)	4.444	0.108	0.460	0.041
	Middle	0	13	4	17(85)	7.937	0.005*	0.630	0.003*
	Ring	0	14	2	16(80)	5.185	0.023	0.509	0.022
	Little	0	13	4	17(85)	7.937	0.005*	0.630	0.003*
4 (With habit without lesion)	Thumb	1	4	6	11 (55)	7.688	0.104	0.470	0.037
	Index	4	8	3	15 (75)	15.527	0.004*	0.603	0.005*
	Middle	0	11	2	13 (65)	10.139	0.038	0.207	0.382
	Ring	0	11	2	13 (65)	0.495	0.482	0.157	0.508
	Little	0	16	1	18 (90)	8.889	0.003*	0.667	0.001*
5 (Control)	Thumb	0	4	11	15 (75)	7.472	0.024	0.604	0.005*
	Index	0	14	3	17(85)	9.479	0.009	0.645	0.002*
	Middle	0	15	0	15 (75)	0.392	0.531	-0.140	0.556
	Ring	0	13	5	18 (90)	12.381	0.000*	0.787	0.000*
	Little	0	15	3	18 (90)	10.588	0.001*	0.728	0.000*

1270



*Significant at $P < 0.05$. OSMF: Oral submucous fibrosis, OL: Oral leukoplakia, OSCC: Oral squamous cell carcinoma

DISCUSSION

Over the many years, researchers tried to come up with ways to detect oral PMDs and cancer to prevent it from further spreading in the body or early diagnosis. One such method used is dermatoglyphics.[7] It is the study of the naturally occurring patterns on the surface of the hands and feet.[3] The analysis of fingerprints does not involve sophisticated equipment and it is a noninvasive procedure. Hence, the present study was conducted to determine the association between the fingerprint patterns and the PMDs and oral cancer. It was observed that the arch pattern was observed in PMDs and oral cancer, with habit without lesion and in the control group was 1%–3%, 11% and 2%, respectively. In the present study, loop pattern was predominantly observed in the control group followed by with habit without lesions, OSCC, OL and OSMF group. Karthik conducted a study on PMDs, OSCC and individuals with habits without lesions in the Chennai population.[8] In their study, they found that the loop pattern was predominant with decreasing frequency of whorl and arch pattern in all the study groups, which is similar to the present study. Deepa *et al.* conducted a study on PMDs and OSCC in the Karnataka population, in their study, they found that arch pattern was commonly found in PMDs and OSCC,[2] which was contradictory to the present study, in which the arch pattern was predominant in the with habit without lesion group. These might be due to the variation in population because the present study was conducted in west Indian populations. As Galton *et al.* demonstrated different racial groups having biological variations of different fingerprint patterns.[1] A study conducted by Singh *et al.* in the Bihar population also found a similar result as seen in Deepa *et al.*[9] The arch pattern was predominant in PMDs than individuals with habit without lesion and control group, which was contradictory to the present study, in which the arch pattern was predominant in

the with habit without lesion group. Darna *et al.* did a study on subjects with lichen planus, OSMF and leukoplakia.[10] They show an increase in the frequency of whorl pattern and a decrease in arch pattern in the control group than other groups, which was contradictory to the present study. In the present study, loop patterns were found with higher frequency in the control group than other groups. This may be because the present study did not include lichen planus as a PMDs, unlike their study. The present study showed an increased frequency of whorl pattern among OSMF subjects when compared to healthy subjects. This was in concordance with the study by Kumar *et al.*[11] and contradictory to the study by Aditya *et al.* in 2016.[12] They have shown a predominance of whorl pattern in the control group. In their study, all the PMDs were included in one group, unlike the present study where the PMDs like OL, OSMF were grouped as a separate group. The study conducted by Dutta *et al.* in 2016, shows a decreased arch pattern and whorl pattern in OSMF subjects than control group,[13] which was dissimilar to the present study. The present study shows that the whorl pattern and arch pattern increased in OSMF group subjects than in a control group. In the case of habit without lesion, it was observed that the loop pattern predominated which was similar to the study done by Awasthy *et al.* in 2018.[4] Munishwar *et al.* reported that loop patterns were predominant in the control group (57.60%) than in individuals with OSMF (43.60%) which was in concordance with the present study in which the control group had 69.5% and the OSMF group had a 54.5% of the distribution of loop pattern.[14] In the present study, loop patterns were predominant in the control group which was similar to the study done by Kulkarni *et al.* in 2020.[7] In the present study, right and left fingerprint comparison was also done for all the lesions, which shows right and left association and correlation among all the

groups except in with habit without lesion group showed a statistically significant association and correlation. The highest correlation was found in Group 2. Based on that, it can be assumed that right and left symmetry was seen in OSMF subjects than OL, OSCC and with habit without lesion subjects. The right and left symmetry of the fingerprint patterns was done in all the groups (finger-wise). Among all the 5 groups, the control group shows the highest correlation (0.787) in ring finger which was statistically significant, whereas the negative correlation (-0.123) was seen in the middle finger of Group 1. Among all the five fingers, best correlation was found in the thumb in Groups 1 and 2 which was 0.685 and 0.706, respectively. Whereas in Group 3, best correlation (0.630) was found in the middle finger and little finger. In Group 4, highest correlation was seen in the little finger which was 0.667. In Group 5, highest correlation was found in the ring finger (0.787), intermittent correlation (0.728) was seen in the little finger, whereas negative correlation was found in the middle finger (-0.140). These findings suggested that the right and left fingerprints were not symmetrically distributed. Hence, based on these, it can be assumed that we cannot depend only on the right or left fingerprint; we have to take all ten fingerprints. Because of the small sample size, it is not possible to conclude this. A further study with a large sample size is needed to check the symmetry between the right and left fingerprints in PMDs and in oral cancers.

CONCLUSION

In the present study, distribution of the arch, whorl and loop patterns among the five different groups showed a significant difference only in the arch pattern. This is because of arch pattern has higher frequency distribution in with habit without group. The limitation of our study is the smaller sample size, based on this sample size, we cannot conclude that the results obtained apply to the Indian population. Further study is needed with a large sample size with age, sex, race and religion matched healthy individuals.

REFERENCES

1. Lakshmana N, Ravikiran A, Samatha Y, Nayyar AS, Vamsi Pavani B, Kartheeki B. Role of digital and palmar dermatoglyphics in early detection of oral leukoplakia, oral submucous fibrosis and oral squamous cell carcinoma patient. *Adv Hum Biol.* 2016;6:136–41. [Google Scholar]
2. Deepa J, Devi Y, Kantraj B, Nagaraju R. Role of dermatoglyphics in malignant and potentially malignant disorders of the oral cavity: A cross sectional study. *J Indian Acad Oral Med Radiol.* 2014;26:379. [Google Scholar]
3. Gupta A, Karjodkar FR. Role of dermatoglyphics as an indicator of precancerous and cancerous lesions of the oral cavity. *Contemp Clin Dent.* 2013;4:448–53. [PMC free article] [PubMed] [Google Scholar]
4. Awasthy D, Maheshwari VJ, Maurya R, Shukla C. Variations in dermatoglyphic patterns in oral submucous fibrosis and leukoplakia patients with and without adverse oral habits. *JIAOMR.* 2018;30:271–4. [Google Scholar]
5. Cloos J, Spitz MR, Schantz SP, Hsu TC, Zhang ZF, Tobi H, et al. Genetic susceptibility to head and neck squamous cell carcinoma. *J Natl Cancer Instit.* 1996;88:530–5. [PubMed] [Google Scholar]
6. Gangane SD. 2nd. New Delhi: B.L. Churchill Livingstone Pvt. Ltd; 2001. Human Genetics. [Google Scholar]
7. Kulkarni VV, Chaudhari AR, Kulkarni AS. Comparison of dermatoglyphic patterns in oral leukoplakia and oral submucous fibrosis patients. *Int J Res Med Sci.* 2020;8:153. [Google Scholar]
8. Karthik MD. Susceptibility for oral squamous cell carcinoma and potentially malignant disorders in patients with and without tobacco habits: Dermatoglyphics correlation. *J Crit Rev.* 2020;7:3523–30. [Google Scholar]
9. Singh S, Iqbal A, Nazeer J, Singh R, Rahman Z. Role of dermatoglyphics in malignant and potentially malignant disorders of the oral cavity: A cross-sectional study. *IOSR J Dent Med Sci.* 2017;16:101–5. [Google Scholar]

10. Darna G, Sudhakara R, Rajesh R, Sruthi N, Tungala R, Teja N, et al. Unravelling "The myth-dermatoglyphics in oral potentially malignant disorders" *Int J Curr Res*. 2018;10:65741–6. [Google Scholar]
11. Kumar S, Kandakurti S, Saxena VS, Sachdev AS, Gupta J. A dermatoglyphic study in oral submucous fibrosis patients. *JIAOMR*. 2014;26:269–73. [Google Scholar]
12. Aditya A, Gaikwad S, Jangam DK, Vinay V, Joshi S, Gaikwad S. Analysis of finger prints pattern in patients with potentially malignant disorders: A cross-sectional study. *IOSR J Dent Med Sci*. 2016;15:121–4. [Google Scholar]
13. Dutta N, Shetty R, Pandey V, Nayak SK, Rathore N. Comparison of finger print patterns in patients with and without oral submucosis fibrosis - a dermatoglyphics study. *Int J Contemp Med*. 2016;3:1172–3. [Google Scholar]
14. Munishwar PD, Thiyam B, Veerabhadrapa RS, Singh D, Tyagi K, Shah S. Qualitative analysis of dermatoglyphics in oral submucous fibrosis. *JIAOMR*. 2015;27:207–212. [Google Scholar]

