



## Arthroscopic Treatment of Unstable Distal Clavicle Fracture (Neer's type II) by Coracoclavicular Double-Button Fixation technique

Mohamed F.Elhalawany<sup>a</sup>, Ahmed Taher<sup>b</sup>, Ahmed Saied Mohammed<sup>a</sup>, Lotfy M. Shwitter<sup>a</sup>, Usama Gaber Abdalla<sup>a</sup>.

<sup>a</sup>Lecturer of Orthopedic Surgery Department, Faculty of Medicine, Al-Azher University, Egypt,

<sup>b</sup>Master degree of orthopedic surgery.

\*Corresponding authors at Department of Orthopedic Surgery, Faculty of Medicine, Al-Azher University, Egypt.

E-mail address: [mohamed.halawany1234@gmail.com](mailto:mohamed.halawany1234@gmail.com), Mobile:00201004196227.

### ABSTRACT

**Background & Purpose:** More recently, arthroscopically assisted fixation techniques Based on previous reports of excellent clinical outcome of indirect coracoclavicular stabilization, we present our experience in performing a minimally invasive, closed-loop, double endobutton stabilization of Neer's type II distal clavicle fractures, using the TightRope system (Arthrex, Naples, FL, USA). This study was conducted to evaluate the efficacy and safety of Arthroscopic Coracoclavicular Double-Button Fixation technique in patients with unstable distal clavicle fracture (Neer's type II).

**Study design:** Prospective, cohort study.

**Setting:** Al-Azhar university hospitals.

**Methods:** We included 28 unstable distal clavicle fracture patients (age from 20 – 52 years old), with Neer's type II fracture of the clavicle using arthroscopic Coracoclavicular Double-Button Fixation technique. Post-operative follow-up assessment (at 6 months) included assessment of American Shoulder and Elbow Surgery Score (ASES score), Constant score, External rotation, Forward Flexion, and Abduction degrees, along with assessment of complications occurrence and hospital stay duration.

**Results:** In the studied population, the mean age of all patients was (31.2 ± 9.6) years. Regarding gender of the patients, the majority (75%) of patients were males; while (25%) were females. Regarding post-operative efficacy data (functional scores and range of motion), the average ASES score was (90.6 ± 2.6), the average Constant score was (92.9 ± 2.57), the average degree of external rotation was (82.85 ± 7.8), the average degree of forward flexion was (164.7 ± 5.9), and the average degree of abduction was (168.6 ± 7.2). Regarding post-operative safety data, (10.7%) of patients suffered complications, with (3.6%) had infection and (7.1%) had delayed union, with overall hospital stay of 1 day.

**Conclusion:** To conclude, arthroscopic Coracoclavicular Double-Button Fixation techniques showed a significantly better post-operative efficacy regarding functional scores and range of motion degree. Patients with unstable distal clavicle fracture especially (Neer's type II), showed highly significant increase in post-operative ASES score, Constant score, External rotation, Forward flexion, and Abduction assessments after only 6 months of arthroscopic management by Coracoclavicular Double-Button Fixation technique.

**Keywords:** Unstable Distal Clavicle Fracture, Coracoclavicular Double-Button Fixation, Neer's type II.

DOI Number: 10.14704/nq.2022.20.6.NQ22330

NeuroQuantology 2022; 20(6):3259-3273



invasive, closed-loop, double button stabilization of acute Neer's type II distal clavicle fractures, using the TightRope system (Arthrex, Naples, FL, USA).

**Hypothesis:** Arthroscopic coracoclavicular Double-Button Fixation technique for patients with acute Neer's type II distal clavicular fractures yields good clinical outcome on short term with comparable safety to the open technique.

## PATIENTS AND METHODS

### PATIENTS:

A total of 28 successive acute unstable distal clavicle fracture patients were enrolled in the study between May 2020 and June 2021. All patients underwent arthroscopic coracoclavicular double button fixation by the same surgeon (M.EH) within 48 hours of admission.

### Study design:

- Prospective, cohort study.

### Inclusion criterion:

- Patients with acute displaced Neer's type II fracture of the clavicle.

### Exclusion criteria:

- Patients with Neer's type I-III-IV fracture of the clavicle
- Patients with fractures more than 6 weeks old.
- Skeletally immature patients and patients > 60 years.
- Patients with concomitant fractures in the same limb or in cervical spine.
- Patients who fail to follow up for months at least.

## INTRODUCTION

Clavicle fractures are common injuries in clinical practice, with fractures of the distal third of the clavicle, including the lateral attachment sites of the coracoclavicular (CC) ligament representing 15 % of cases (1).

Neer's classification is normally used to describe this type of clavicular fractures. Neer's type II (there is IIa and IIb mention) fractures occur proximal to the CC ligament, disrupting the conoid ligament, which forms the posterior and medial fasciculus of the CC ligament, which is the main stabilizer of the clavicle. (2).

These fractures can be significantly displaced as a result of strong deforming forces. The trapezius muscle pulls the medial fragment superiorly and posteriorly and the weight of the arm on the shoulder girdle pulls the distal fragment inferiorly and anteriorly (3).

Different surgical approaches have been developed for the treatment of Neer's type II fractures, including direct osteosynthesis, using a locking plate, hook plate, or K-wire, or indirect stabilization of the CC, using various suture materials or tendon grafts for reconstruction (4).

More recently, arthroscopically assisted fixation techniques based on previous reports of excellent clinical outcome of indirect CC stabilization were introduced (5). These procedures may have several advantages: they are minimally invasive, they do not violate the delicate subacromial area, and the implants do not need to be removed. Complex arthroscopic surgery, on the other hand, necessitates experience and training for both the surgeon and the operating room crew (6).

Here we present the short-term clinical outcome of minimally

## METHODS

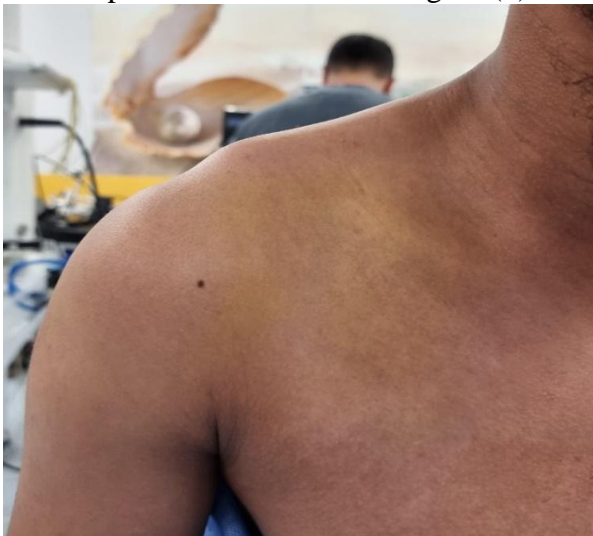
**Patients were subjected (pre-operatively) to the following:**

- ☑ Full history taking
- ☑ Full clinical examination.
- ☑ Assessment of American Shoulder and Elbow Surgery Score (ASES score) (7).
- ☑ Assessment of Constant score (8).
- ☑ Assessment of External rotation degree.
- ☑ Assessment of Forward Flexion degree.
- ☑ Assessment of Abduction degree.

### Management

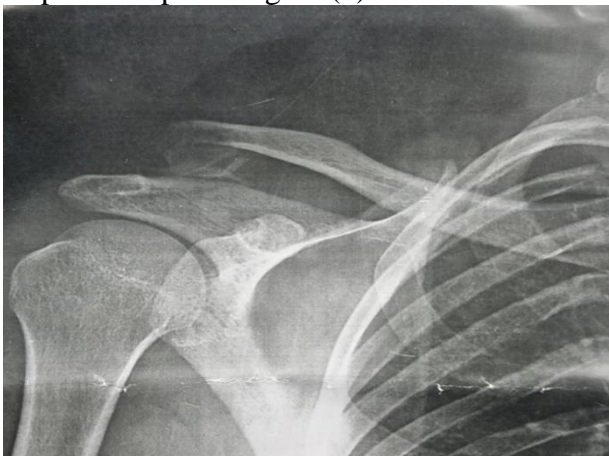All patient represented clinically by pain, swelling, tenderness, on the lateral end of clavicle and deformity which was the proximal fragment of the clavicle being drawn upwards and backwards figure (1).

3261



**Figure (1):** *The author's photos which described the deformity of Rt distal clavicle fracture which was the proximal fragment being drawn upwards and backwards.*

Radiologically represented on anterior posterior view the proximal fragment displaced superior figure (2).



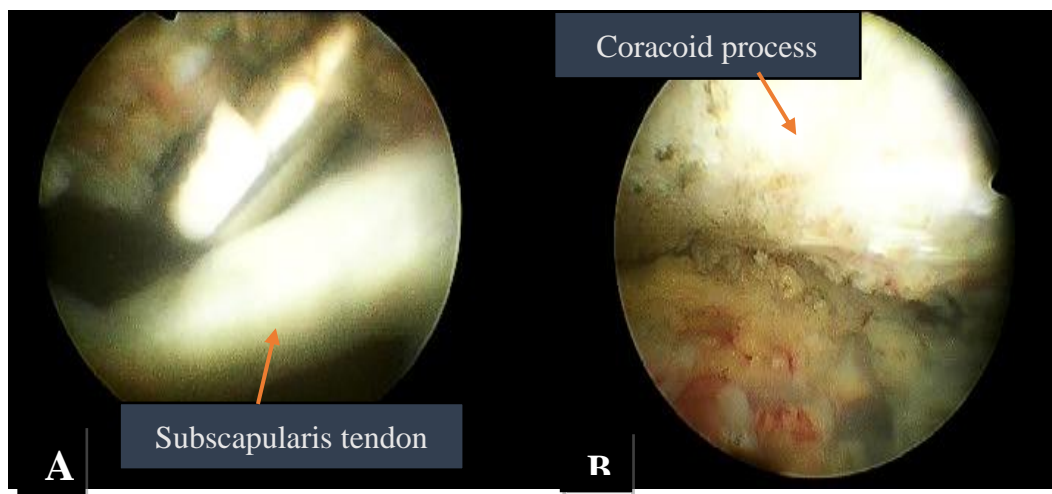
**Figure (2):** *Rt shoulder x-ray (AP) view show the proximal fragment of the clavicle displaced superior.*

### Surgical steps (Coracoclavicular Double-Button Fixation technique):

All surgical procedures were performed by a single senior orthopedic surgeon. The patient was placed in the beach chair position, without any traction, and operated on under general anesthesia.

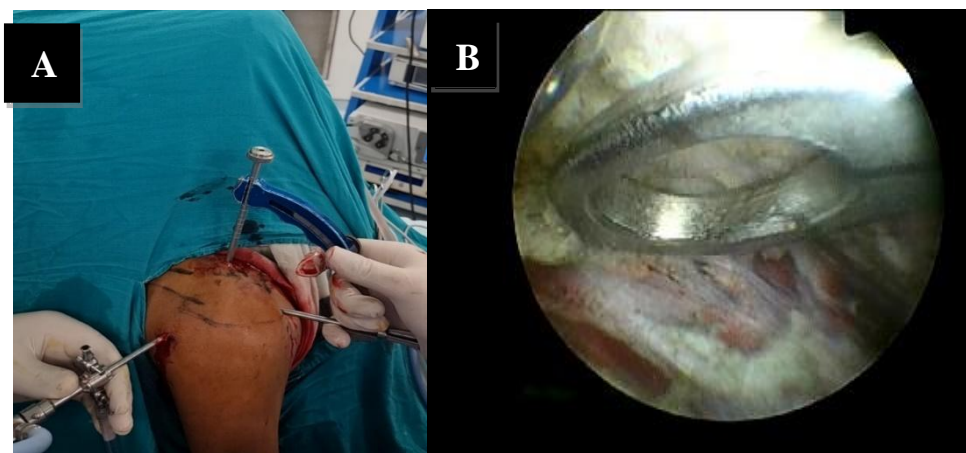
First, a posterior portal was created with an 8-mm stab incision 2-cm inferior and 1-cm medial to the posterior lateral tip of acromion and used for joint exploration. Then, an anterior working portal was created using an outside-in technique which was 8 -mm stab incision halfway between the tip of the coracoid process and the anterior aspect of the acromion. A finger depressed the skin to identify the rotator interval. A spinal anesthesia needle was then used to locate the correct position for skin incision.

The subscapularis bursa was resected using a radiofrequency ablator until the base of the coracoid process could be visualized figure (3).



**Figure (3):** The author's arthroscopic photo described: (A) Release of subscapularis bursa by radiofrequency, (B) Complete release of bursa and visualized coracoid process.

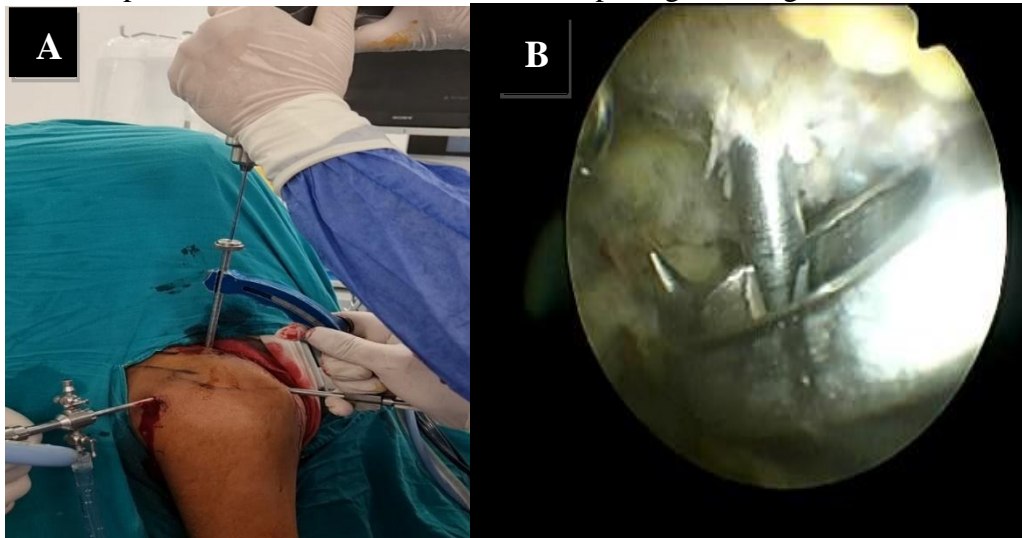
A drill guide was introduced through the anterior portal and centered on the under surface of the base of the coracoid process through using a C- guide figure (4).



**Figure (4):** (A) The author's intraoperative photo described one limb of the guide was introduced through the anterior portal, and another limb was rested on the

*superior surface of the clavicle. (B)The author's arthroscopic photo described the limb of the guide rested on the base of coracoid process.*

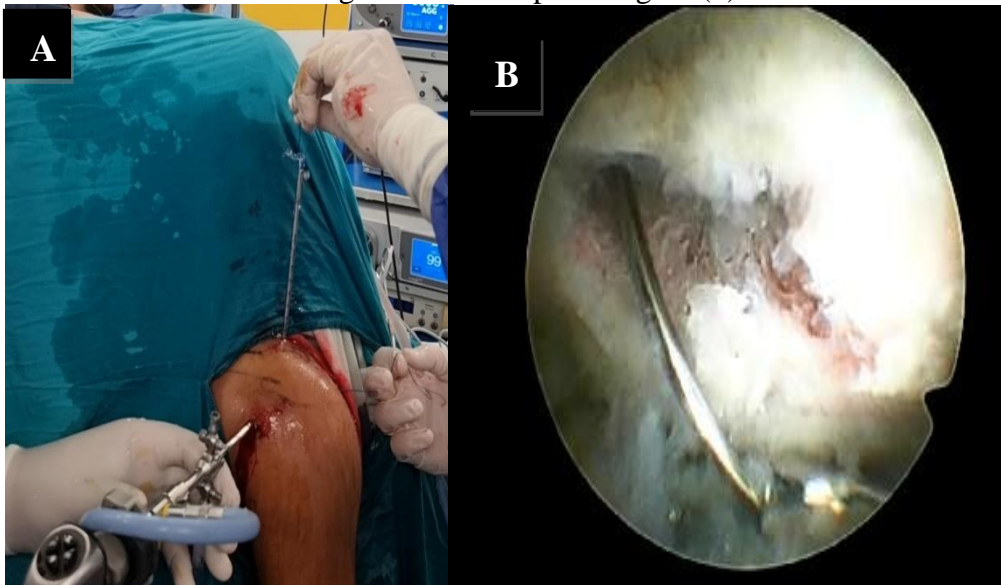
A 2 cm incision was made over the proximal fragment of the clavicle just medial to the fracture. Good positioning is critical because an anteriorly or posteriorly placed tunnel may break through the remaining cortex of the clavicle and lead to implant loosening or loss. Using arthroscopy, fluoroscopy and the guide, a 2 mm K-wire was inserted from the proximal fragment of clavicle toward the coracoid figure (5), and a 4 mm hole was created following the K-wire through the clavicle and the coracoid process with a cannulated drill, with passages through the four cortices.



3263

*figure. (5): The author's intraoperative photo described the insertion of K- wire through the guide. (B)The author's arthroscopic photo described the K- wire was passed through the four cortices and got out from the inferior surface of coracoid process and hole of guide.*

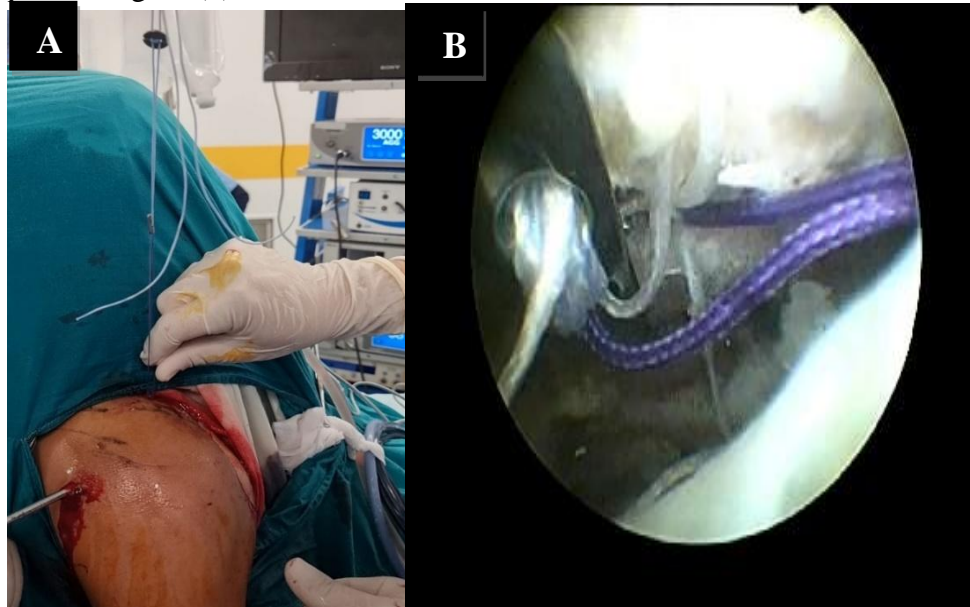
The K-wire was then withdrawn, leaving the drill in place, and replaced by a guide, which was retrieved through the anterior portal figure (6).



*Figure (6): (A)The author's intraoperative photo described removal of K- wire and insertion of guide wire through the cannulated drill. (B) The author's*

*arthroscopic photo described when the guide pulled from cannulated drill through anterior portal.*

The Tight Rope TM-system (Arthrex; Naples, FL) was then inserted through the tunnels using a wire passer through the cannulated mesh, from the clavicle to the coracoid, and the button was flipped so as to fix under the surface of the coracoid process figure (7).



**Figure (7):** (A) *The author's intraoperative photo described when the Tight Rope inserted through the tunnel of the proximal end of the clavicle. (B) The author's arthroscopic photo described when the button fixed on the inferior surface of coracoid.*

Finally, reduction of the fracture and fluoroscopic visualization with a downward pressure on the proximal fragment of the clavicle, the sutures were then tightened and tied upon the clavicle. Fluoroscopic control was used to confirm reduction of the fracture and positioning of the implants. and Finally closure of the wound was done using 2/0 vicryl for subcutaneous tissue and 3/0 nylon for skin.

#### **Postoperative rehabilitation protocol**

Immobilization was achieved by a shoulder-arm sling for 4 weeks postoperatively. At the end of the second week, sutures were removed, the sling was removed at least three times per day, and shoulder pendulum exercises were performed. At the end of the fourth week, the sling was removed, and shoulder range of motion (ROM) exercises were allowed until 6–8 weeks. Active assisted exercises were started after confirming radiological union at 8 weeks postoperatively. Active strengthening exercises were given after 12 weeks. Routine clinical and radiological follow-up assessments were performed by the senior author (MK) at 2, 6, 12, 24 weeks and the last assessment at 24 weeks was used in this study.

#### **Post-operative follow-up assessment (at 6 months):**

- Assessment of ASES score.
- Assessment of Constant score.
- Assessment of External rotation degree.
- Assessment of Forward Flexion degree.
- Assessment of Abduction degree.
- Assessment of complications occurrence.
- Assessment of hospital stay.

**Ethical Considerations:**

- All patients included in this study only after taking informed consent.

**Statistical analysis:**

The sample size was determined based on prior data that of **Michener et al .** (7). As their reported pre-operative external rotation degree was ( $45.33 \pm 15.52$ ), and the post-operative external rotation degree was ( $61.33 \pm 12.46$ ) degrees.

Then 28 total subjects were needed to be able to reject the null hypothesis that the pre- and post-operative external rotation degree are comparable with probability (power) 80%. The Type I error probability associated with this test of this null hypothesis is 0.05.

Tests of significance (Paired Student's t test, logistic regression analysis, and Pearson's correlation) were used. Statistical analysis was carried out using MedCalc ver. 20 (MedCalc, Belgium).

3265

**RESULTS**

In the studied population, the mean age of all patients was ( $31.2 \pm 9.6$ ) years. Regarding gender of the patients, the majority (75%) of patients were males; while (25%) were females. Regarding basic clinical and fracture data, (75%) of patients had Rt-sided dominant arm, with (67.9%) had Rt-side distal clavicle fracture and (32.1%) had Lt-side distal clavicle fracture.

Regarding mechanism of injury; (50%) of patients had motor vehicle accidents (MVA), (28.6%) had falls, and (21.4%) had sports injuries.

Regarding pre-operative data, the average ASES score was ( $29.75 \pm 3.28$ ), the average Constant score was ( $32.4 \pm 3.8$ ), the average degree of external rotation was ( $28.7 \pm 3.8$ ), the average degree of forward flexion was ( $59.28 \pm 4.6$ ), and the average degree of abduction was ( $59.64 \pm 5$ ).

Regarding intra-operative data, the average days until surgery was ( $1.4 \pm 0.8$ ) days, and the average duration of surgery was ( $33.5 \pm 2.67$ ) min.

Regarding post-operative efficacy data (functional scores and range of motion), the average ASES score was ( $90.6 \pm 2.6$ ), the average Constant score was ( $92.9 \pm 2.57$ ), the average degree of external rotation was ( $82.85 \pm 7.8$ ), the average degree of forward flexion was ( $164.7 \pm 5.9$ ), and the average degree of abduction was ( $168.6 \pm 7.2$ ).

Regarding post-operative safety data, (10.7%) of patients suffered complications, with (3.6%) had infection and (7.1%) had delayed union, with overall hospital stay of 1 day.

**Comparative studies:****Paired comparative studies efficacy data (functional scores and range of motion):**

We further analyzed and compared 28 (paired) unstable distal clavicle fracture patients according to the serial assessments (pre and post-operative); data are shown in the following tables and figures:



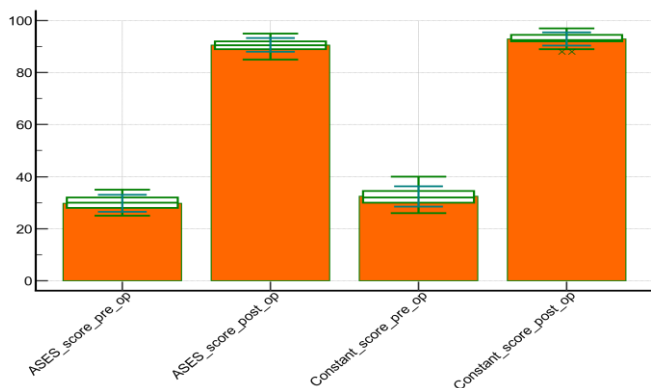
**Table 1: Comparison between unstable distal clavicle fracture patients as regards serial efficacy parameters:**

Variable	Pre-operative assessment	Post-operative assessment	Paired <i>t</i> test
	Mean ± SD	Mean ± SD	P value
<b>ASES score</b>	29.75 ± 3.28	90.6 ± 2.6	< 0.0001**
<b>Constant score</b>	32.4 ± 3.8	92.9 ± 2.5	< 0.0001**
<b>External rotation (°)</b>	28.7 ± 3.8	82.8 ± 7.8	< 0.0001**
<b>Forward flexion (°)</b>	59.28 ± 4.6	164.7 ± 5.9	< 0.0001**
<b>Abduction (°)</b>	59.6 ± 5	168.6 ± 7.2	< 0.0001**

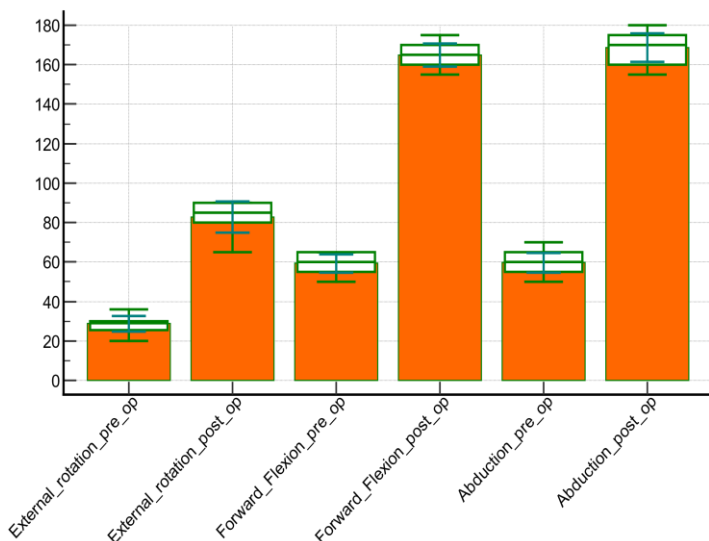
Comparative study between pre-operative and post-operative assessments revealed; highly significant increase in post-operative ASES score, and Constant score ( $p < 0.0001$  respectively).

Comparative study between pre-operative and post-operative assessments revealed; highly significant increase in post-operative External rotation, Forward flexion, and Abduction assessments in distal clavicle fracture patients ( $p < 0.0001$  respectively) ( Table 1, Figure (8), Figure (9)).

3266



**Figure (8): Comparison pre-operative and post-operative ASES and Constant scores assessments.**



**Figure (9): Comparison pre-operative and post-operative External rotation, Forward flexion and Abduction assessments.**

**Correlation studies:**

Correlation studies between **post-operative outcomes**; and its **relative independent predictors (basic clinical, pre-operative and intra-operative variables)** conducted with logistic regression analysis, and Spearman's correlation coefficient (as suitable).

**Table 2: Pearson's correlation analysis for basic clinical / pre-operative Factors associated with post-operative ASES score:**

Associated Factor	Post-operative ASES score	
	r	P
Age (years)	-0.7457	<0.0001**
Pre-operative ASES score	0.6680	=0.0001**
Pre-operative Constant score	0.6704	=0.0001**
Pre-operative External rotation (°)	0.2170	=0.2674
Pre-operative Forward flexion (°)	0.6708	=0.0001**
Pre-operative Abduction (°)	0.4180	=0.026*
Days until surgery (days)	-0.5488	=0.0025**
Duration of surgery (min)	-0.2848	=0.1419

r: Pearson's rho (correlation coefficient).

Pearson's correlation analysis shows that; pre-operative ASES score, Constant score, Forward flexion, and Abduction degree, had a highly significant positive correlation with post-operative ASES score ( $p < 0.01$  respectively).

Pearson's correlation analysis shows that; age, and days until surgery, had a highly significant negative correlation with post-operative ASES score ( $p < 0.01$  respectively) (

Table 2).

**Table 3: Pearson's correlation analysis for basic clinical / pre-operative Factors associated with post-operative Constant score:**

Associated Factor	Post-operative Constant score	
	r	P
Age (years)	-0.7560	<0.0001**
Pre-operative ASES score	0.6981	<0.0001**
Pre-operative Constant score	0.7098	<0.0001**
Pre-operative External rotation (°)	0.2488	=0.2018
Pre-operative Forward flexion (°)	0.6889	=0.0001**
Pre-operative Abduction (°)	0.4647	=0.012*
Days until surgery (days)	-0.5464	=0.0026**
Duration of surgery (min)	-0.2924	=0.1310

r: Pearson's rho (correlation coefficient).

Pearson’s correlation analysis shows that; pre-operative ASES score, Constant score, Forward flexion, Abduction degrees, had a highly significant positive correlation with post-operative Constant score ( $p < 0.01$  respectively).

Pearson’s correlation analysis shows that; age, and days until surgery, had a highly significant negative correlation with post-operative Constant score ( $p < 0.01$  respectively) (**Table 3**).

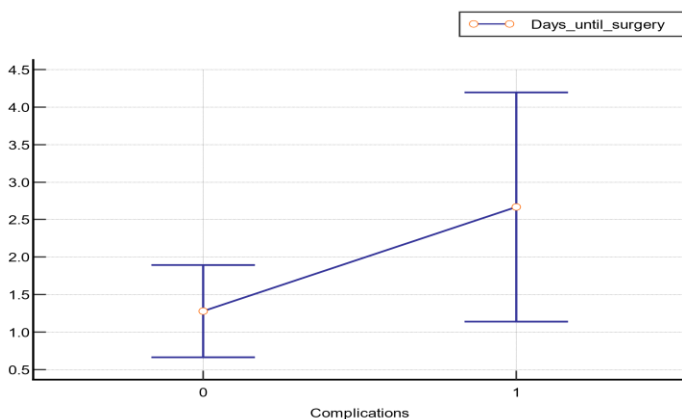
**Table 4: Logistic regression model for the Factors affecting complications occurrence using Forward method:**

Predictor Factor	Coefficient	OR	P value
(Constant)	-4.88886		
<b>Days until surgery</b>	1.48965	4.4356	0.033*

Other factors excluded from the model as ( $p \text{ value} > 0.1$ ). OR: odds ratio.

Logistic regression analysis shows that; after applying (Forward method) and entering some predictor variables; the increase in days until surgery; had an independent effect on increasing the probability of complications occurrence; with significant statistical difference ( $p = 0.033$ ) (

Table 4, Figure (10)).



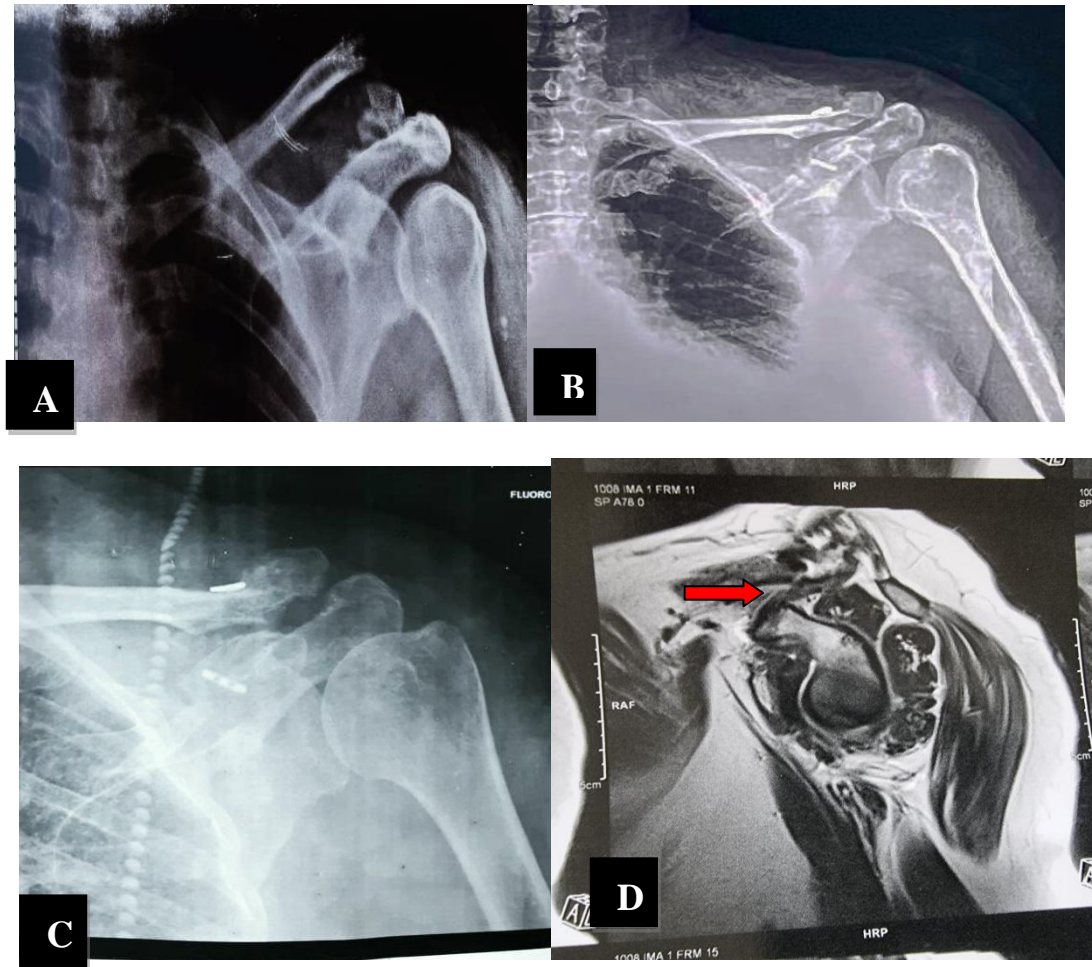
**Figure (10): Correlation between days until surgery and complications.**

**Case example:**

Female patient ,45 years, presented by left distal clavicle fracture, radiological evaluation by x-ray on Lt shoulder represented Neer’s type II fractures of distal clavicle figure. (11-A), and he was treated by this technique which describe in this study and immediate postoperative plain x-ray show good reduction and fixed by Tight Rope fig. (11-B).

Three months after the operation, the plane x-ray and MRI showed union of the fracture and healing of coracoclavicular ligament figure (11-C-D).





**Figure 11: Preoperative and postoperative X-rays of Lt Neer type II distal clavicle fracture and photographs demonstrating range of motion. (A) Preoperative anteroposterior Lt shoulder X-ray. (B) Immediate postoperative anteroposterior Lt shoulder X-ray demonstrating distal clavicle fracture good reduction and fixed by Tight Rope. (C) Three months postoperative Lt shoulder X ray demonstrating union of the fracture. (D) Three months postoperative MRI of Lt shoulder demonstrating good union and coracoclavicular ligament healing (red arrow marked on (cc) -ligament).**

minimally invasive reconstruction of coracoclavicular ligament (CC), and had Coracoclavicular Double-Button Fixation technique.

All patients were subjected to full history taking, full clinical examination, assessment of American Shoulder and Elbow Surgery Score (ASES score), Constant score, External rotation, Forward Flexion, and Abduction degrees. Then, Coracoclavicular Double-Button Fixation technique was used in all

## DISCUSSION

This was a prospective cohort study conducted on 28 patients with unstable distal clavicle fracture; to evaluate the efficacy and safety of Arthroscopic Coracoclavicular Double-Button Fixation technique in patients with unstable distal clavicle fracture (Neer type II).

We included 28 unstable distal clavicle fracture patients (age from 20 – 52 years old), with Neer's type II fracture of the clavicle using a

and a 49-year-old patient with Gougerot-Sjogren syndrome developed symptomatic acromioclavicular joint osteoarthritis one year after surgery. Despite a correct initial reduction, a 55-year-old patient experienced implant failure at 6 weeks, resulting in a nonunion.

**Zheng et al., 2019**(10) also reported that, there were no serious problems, such as a loss of reduction or a deep infection. There was only one complication, a peri-implant fracture of the coracoid process.

**Yagnik et al., 2021**(12)concluded in their meta-analysis that, Complications were reported in 14 of the 15 investigations, with a total complication rate of 27.4%. However, only 12% of them were classified as significant difficulties, and only 6% required a reoperation due to hardware-related complications.

We further analyzed and compared 28 (paired) unstable distal clavicle fracture patients according to the serial assessments (pre and post-operative);

Comparative study between pre-operative and post-operative assessments revealed; highly significant increase in post-operative ASES score, and Constant score ( $p < 0.0001$  respectively). Which came in agreement with **Wurm et al., 2021**(11), **Zheng et al., 2019**(10), **Kapicioglu et al., 2021**(13), **Rose et al., 2018**.(14), and **Yagnik et al., 2021**(12).

**Wurm et al., 2021**(11)reported that, the functional outcome was satisfactory to exceptional (ASES 94.7, Constant Score 85.1). All patients returned to sports after surgery, with a mean time to return to sport of 4.6 (3–9) months.

**Zheng et al., 2019**(10)also reported that, the mean pain score at the latest follow-up evaluation was 1.40, with an ASES score of 88.27 and a Constant score of 92.33.

patients. Post-operative follow-up assessment (at 6 months) included assessment of American Shoulder and Elbow Surgery Score (ASES score), Constant score, External rotation, Forward Flexion, and Abduction degrees, along with assessment of complications occurrence and hospital stay duration.

**Loriaut et al., 2015**(9)reported that, the most common cause of injury was traffic accidents ( $n = 11$ ), followed by sports injuries ( $n = 7$ ) and ordinary falls ( $n = 3$ ). In fifteen patients, the dominant arm was affected.

Regarding post-operative efficacy data (functional scores and range of motion), the average ASES score was ( $90.6 \pm 2.6$ ), the average Constant score was ( $92.9 \pm 2.57$ ), the average degree of external rotation was ( $82.85 \pm 7.8$ ), the average degree of forward flexion was ( $164.7 \pm 5.9$ ), and the average degree of abduction was ( $168.6 \pm 7.2$ ). Which came in agreement with **Flinkkilä et al., 2015**(6), and **Wurm et al., 2021**(11).

**Flinkkilä et al., 2015**(6)reported that, the average post-operative Constant score was ( $93 \pm 7$ ).

**Wurm et al., 2021**(11)also reported that, the average post-operative External Rotation was ( $40.9 \pm 14.5$ ), Internal Rotation was ( $90 \pm 15.4$ ), flexion ( $165.4 \pm 27.3$ ) and abduction was ( $168.5 \pm 23.8$ ) degrees .

Regarding post-operative safety data, (10.7%) of patients suffered complications, with (3.6%) had infection and (7.1%) had delayed union, with overall hospital stay of 1 day. Which came in agreement with **Loriaut et al., 2015**(9), **Zheng et al., 2019**(10), and **Yagnik et al., 2021**(12).

**Loriaut et al., 2015**(9)concluded that, Postoperative complications were noted in three patients: a 67-year-old patient acquired temporary adhesive capsulitis two months after surgery;

*Erden et al., 2021*(15)also concluded that, return to daily activities and complete range of motion of the afflicted shoulder were achieved in all patients within 6 to 12 weeks. The mean American Shoulder and Elbow Surgeons Shoulder score, Constant-Murley score, and visual analogue scale score at the last postoperative examination were (95.0), (96.2), and (0.4), respectively.

### Conclusion

To conclude, arthroscopic Coracoclavicular Double-Button Fixation technique showed a significantly better post-operative efficacy regarding functional scores and range of motion degree. Patients with unstable distal clavicle fracture especially (Neer's type II), showed highly significant increase in post-operative ASES score, Constant score, External rotation, Forward flexion, and Abduction assessments after only 6 months of arthroscopic management by Coracoclavicular Double-Button Fixation technique.

### Acknowledgments

#### Conflict of interest

None.

### Funding

Self-funding.

### Ethical approval

Patients had informed consent.

### Authorship

All the listed authors contributed significantly to the conception and design of study, acquisition, analysis, and interpretation of data and drafting of the manuscript, to justify authorship.

## REFERENCES

*Kapicioglu et al., 2021*(13)also reported that, At the last follow-up, all patients had anatomic reduction and bone repair. The average wait time before surgery was two days (range: one to four). The mean ASES, Constant-Murley score, and VAS score at the last follow-up were 92.6, 96.2, and 0.47, respectively. All patients were able to return to work and participate in sports activities.

*Rose et al., 2018*(14)also reported that, Scores from the American Shoulder and Elbow Surgeons improved from 40.3 to 86.7 (P 0.001). The mean score on the Simple Shoulder Test improved from 2.7 to 11 (P 0.001). Subjective Shoulder Value increased from 41.6 to 91.4 points.

*Yagnik et al., 2021*(12)concluded in their meta-analysis that, the majority of the fractures (97%) were treated with arthroscopic fixation using a cortical button coracoclavicular stabilization surgical method. In 94.1 percent of the fractures, bone union was seen. At the final follow-up, the majority of patients had good to exceptional outcomes. The most commonly utilised functional outcome metric was the Constant-Murley score; the pooled mean Constant score was 93.06.

Comparative study between pre-operative and post-operative assessments revealed; highly significant increase in post-operative External rotation, Forward flexion, and Abduction assessments in distal clavicle fracture patients (p < 0.0001 respectively). Which came in agreement with *Wurm et al., 2021*(11), and *Erden et al., 2021*(15).

*Wurm et al., 2021*(11)reported that, At the final follow-up, 39/46 (84.8 percent) patients were satisfied with the surgical outcome and had no limitations in range of motion. However, 20/46 (43.5%) of the patients noticed discomfort over the surgical region.

9. Loriaut P, Moreau P-E, Dallaudiere B, Pélissier A, Vu HD, Massin P, et al. Outcome of arthroscopic treatment for displaced lateral clavicle fractures using a double button device. *Knee Surgery, Sports Traumatology, Arthroscopy* 2015;23:1429–33.
10. Zheng YR, Lu YC, Liu CT. Treatment of unstable distal-third clavicle fractures using minimal invasive closed-loop double endobutton technique. *Journal of Orthopaedic Surgery and Research* 2019;14:1–7.
11. Wurm M, Zyskowski M, Pesch S, Biberthaler P, Kirchhoff C, Beirer M. Good to Excellent Functional Outcome and High Return to Sports Rate after Operative Treatment of Unstable Lateral Clavicle Fractures: Comparison of Two Coracoclavicular Button Fixation Techniques. *Journal of Clinical Medicine* 2021;10:4685.
12. Yagnik GP, Seiler JR, Vargas LA, Saxena A, Narvel RI, Hassan R. Outcomes of Arthroscopic Fixation of Unstable Distal Clavicle Fractures: A Systematic Review. *Orthopaedic Journal of Sports Medicine* 2021;9:23259671211001772.
13. Kapicioglu M, Erden T, Bilgin E, Bilsel K. All arthroscopic coracoclavicular button fixation is efficient for Neer type II distal clavicle fractures. *Knee Surgery, Sports Traumatology, Arthroscopy* 2021;29:2064–9.
14. Rose MT, Noyes MP, Denard PJ. Arthroscopy-assisted Treatment of Displaced Distal Clavicle Fractures Utilizing Curved Buttons and Suture Tape With a Single
1. Postacchini F, Gumina S, DeSantis P, Albo F. Epidemiology of claviclefractures. *J Shoulder Elb Surg.* 2002;11:452–6.
2. Neer CS 2nd. Fractures of the distal third of the clavicle. *Clin Orthop RelatRes.* 1968;58:43–50.
3. Robinson CM, Cairns DA. Primary nonoperative treatment of displacedlateral fractures of the clavicle. *J Bone Joint Surg.* 2004;86:778-782.
4. Bezer M, Aydin N, Guven O. The treatment of distal clavicle fractures withcoracoclavicular ligament disruption: a report of 10 cases. *J Orthop Trauma.*2005;19:524–8.
5. Hanflik A, Hanypsiak BY, Greenspoon J, Friedman DJ. Open reductioninternal fixation of distal clavicle fracture with supplementary buttoncoracoclavicular fixation. *Arthrosc Tech.* 2014;3:e551–4.
6. Flinkkilä T, Heikkilä A, Sirniö K, Pakarinen H. TightRope versus clavicular hook plate fixation for unstable distal clavicular fractures. *European Journal of Orthopaedic Surgery & Traumatology* 2015;25:465–9.
7. Michener LA, McClure PW, Sennett BJ. American Shoulder and Elbow Surgeons Standardized Shoulder Assessment Form, patient self-report section: reliability, validity, and responsiveness. *Journal of Shoulder and Elbow Surgery* 2002;11:587–94.
8. Constant CR, Murley AH. A clinical method of functional assessment of the shoulder. *Clinical Orthopaedics and Related Research* 1987:160–4.



Arthroscopic coracoclavicular button fixation versus anatomic locking plate fixation for unstable distal clavicular fractures. JSES International 2021;5:835–9.

Coracoclavicular Tunnel. Techniques in Hand & Upper Extremity Surgery 2018;22:94–8.  
15. Erden T, Kapicioglu M, Ersen A, Toker B, Sahin K, Bilisel K.

