



Examination The Incidence of Dental, Neurological, Cardiovascular and Radiological Problems in Patients Affected by Covid-19 And Method of Drug Therapy in Patients

Mehrra Akanchi¹, Mohammad reza Shafiei², Mohammad hadikamgar amaleh³, HadiKaseb Ghane⁴, Shaghayegh Gosalipour^{5*}

Abstract

This study has done a systematic review of drug therapy and assessment of the occurrence of dental and neurological problems in patients affected by covid-19. There are various reasons that can cause an infection in the tooth. One of the most common causes of tooth infection is root canal treatments you have had in the past. Unfortunately, bacteria grow in this area and can lead to infection. Having an infection in the tooth can be very dangerous. Because it may spread to other parts of the body and cause serious problems. For this reason, it is very important to recognize the symptoms of infection. When a crack or cavity is formed on the tooth, if not treated in time, an infection may occur in the tooth. Because these are the gates that can pave the way for bacteria to enter your teeth. The most common type of disease is accompanied by episodes of severe pain that may be felt in the eyes, ears, lips, nose, forehead, cheeks, teeth or jaws, or anywhere on the face. The similarity of the symptoms of this complication with the symptoms of common dental diseases is a factor in misdiagnosis. This can lead to a series of unnecessary dental treatments that not only won't solve the problem, but may actually make it worse. Some patients undergo dental treatment at least once before the diagnosis of the disease.

3032

KeyWords: Drug Therapy, Dental and Neurological Problems, Covid 19, Dentistry

DOI Number: 10.14704/nq.2022.20.8.NQ44335

NeuroQuantology 2022; 20(8): 3032-3042

Introduction

Tooth decay, broken teeth, gum infection, systemic diseases that affect the nerves and neurological diseases are some of the almost known reasons that can cause pain in your jaw or face, but perhaps the problem that is hidden from many people is that stress and anxiety are also They can cause jaw pain, facial pain, and also nerve pain. Neural toothache is one of the complications of temporomandibular joint disorder. The temporomandibular joint is the point of connection between the skull bone and the

If you feel pain in this area for no other valid reason, you are most likely diagnosed with temporomandibular joint pain disorder. Temporomandibular joint disorder may be caused by some physical problems that can be detected through radiography or MRI, but apart from physical problems, anxiety and stress will also cause temporomandibular joint disorder, which may cause complications such as nerve pain, toothache, Jaw nerve pain or facial nerve pain.

jaw. This joint allows you to chew, speak, read, etc.

Corresponding author: ShaghayeghGosalipour

Address: ¹Pharm D, Pharmacist, Islamic Azad University of Medical Sciences, Tehran Branch, Tehran, Iran.²Master of Medical Education, Larestan university of medical sciences, Larestan, Iran.³Master of Emergency Nursing, Larestan university of medical sciences, Larestan, Iran.⁴Assistant Professor, Department of Prosthodontics, Faculty of Dentistry, Tehran medical sciences, Islamic Azad university, Tehran, Iran.⁵Dentist, Resident of Dental Protheses, Azad university of medical sciences, Tehran, Iran
E-mail: Wwww.mehrra94@gmail.com, jupiter782.782@gmail.com, kamgarnurse@gmail.com, safa.k.gh@gmail.com,



sh.golalipour@gmail.com

Stress is also the cause of jaw clenching or teeth grinding in people. Due to high stress during the day, patients often release this pressure in the form of teeth grinding during sleep and unconsciously. Sometimes, due to a lot of stress, people even grind

their teeth together during the day (Figure 1). Pressing or grinding the teeth together activates the muscles of the jaw and face and causes these muscles to work or contract and expand.

Figure 1. Drug Therapy



At the same time, the temporomandibular joint, which is the place where the lower and upper jaws are connected, undergoes erosion and extra pressure in this process of pushing the teeth together. The muscles of our jaw and face and temporomandibular joint are able to withstand pressure during eating. These pressures usually last 15 to 20 minutes during eating during the day and night, but due to constant stress and pressure as well as teeth grinding, the muscles of the jaw and face and the temporal joint may be under pressure and activity for 10 to 18 hours and can He mention them as the cause of toothache. This excessive pressure and activity of facial muscles and temporomandibular joint causes their fatigue and erosion and subsequently causes pain in the jaw, face and temporomandibular joint. This pain is caused by inflammation and fatigue of these muscles and joints. Sometimes these high pressures cause teeth to wear down and even break due to grinding teeth. In some cases, these pressures make denervated teeth or teeth that have been sensitive more sensitive than before and sometimes painful, which is known as one of the most common cases of nerve pain. The pain caused by this issue can also be the reason for the onset of migraine headaches or other headaches. Sometimes these pains even cause the pain to be transferred to the neck and back of the head and cause pain in these

areas. Studies show that many people have long-term complications after the complete treatment of Covid-19, or after some time, some of the complications such as hair loss begin. Long-term corona is a complication that many people have suffered, but what does this mean? Regarding this issue, Dr. Asghar Safar Zadeh Khosrow Shahi, a gastroenterologist and a member of the Board of Directors of the Association of Internal Medicine Specialists of Iran, said: Since the end of 2019, when I witnessed the epidemic of the corona virus, many people have undergone treatment and recovered after being infected, but in for some people, the complications of the disease remain for a long time or new complications appear after the recovery period (Figure 2). In this situation, people have long-term corona virus. These people are called long-term carriers. This is because they carry fatigue, incapacity and weakness and other complications caused by the disease with them for a long time. These people have suffered from long-term corona. The immune system is the most important factor in the story of contracting or not contracting any kind of disease. This point should kept in mind when contracting corona virus and also long-term corona virus. This internal specialist says: Some people suffer from long-term corona more than others, such as the elderly, people with immune system defects,

3033



people with special diseases, people with food poverty, people with malnutrition and anyone whose immune system is weak. He is due to a malfunction. People who have contracted the corona virus know that during the corona period, complications that invade the body and mind are not rare, from dizziness to fear of death. In people with long-term corona, some complications remain with the person. Long-term corona appears with the mentioned complications, but sometimes it

targets different organs of the body and disrupts their function. This internal specialist explains that with damage to the organs, a person enters the period of chronic disease as a secondary factor caused by corona. In fact, if the respiratory system was functioning properly before this, Corona will damage it and disrupt the functioning of the lungs. Various organs are exposed to damage, the most prominent of which are the heart, lungs, and brain. Corona can



does not end with these symptoms. It means that it

Figure 2. Six Steps for Successful in vitro Drug Treatment

damage the heart muscles and cause heart failure. This complication causes the occurrence of other heart diseases as well. Corona causes a complication similar to pneumonia in a person. In people with long-term corona virus, the small air sacs or alveoli in the lungs are actually damaged and this is the reason for long-term respiratory disorder. Corona can also affect the brain of young people and cause strokes, seizures and Glen-Barre syndrome, a condition in which a person suffers temporary paralysis. These complications can be the cause of Parkinson's or Alzheimer's in old age or in elderly people. Since the best way to treat pain is to identify and eliminate the source of pain, it is recommended to use different methods to reduce stress. Methods such as meditation, yoga and continuous exercise reduce the stress and anxiety of patients. Sometimes people need the help of psychologists and psychiatrists to reduce stress. In some cases, it is also recommended that a person use a tooth grinding guard while sleeping or use facial muscle exercises and massage therapy to reduce the pressure caused by stress and anxiety

on his joints and facial muscles, but if none of the above cases do not reduce stress and jaw pain, it is recommended to try drug therapy. Some muscle relaxants, stress relievers, or anti-inflammatory medications are useful for treating toothache, facial pain, and nerve pain in the jaw. Some doctors also use botox injections to reduce complications such as teeth pressing together, but this method is not very common among doctors or dentists.

Relationship between systemic diseases and stress and jaw and face pain

In people who have systemic diseases (diseases that involve several organs at the same time) such as diabetes or neurological diseases, stress can aggravate nerve pain in the jaw and face. People who have teeth grinding or grinding their teeth often feel pain in the area of the upper and lower back teeth. Most of these people are not able to point to a tooth that caused them pain and feel the pain in the entire jaw. Sometimes these pressures cause all teeth to become sensitive or gum bone



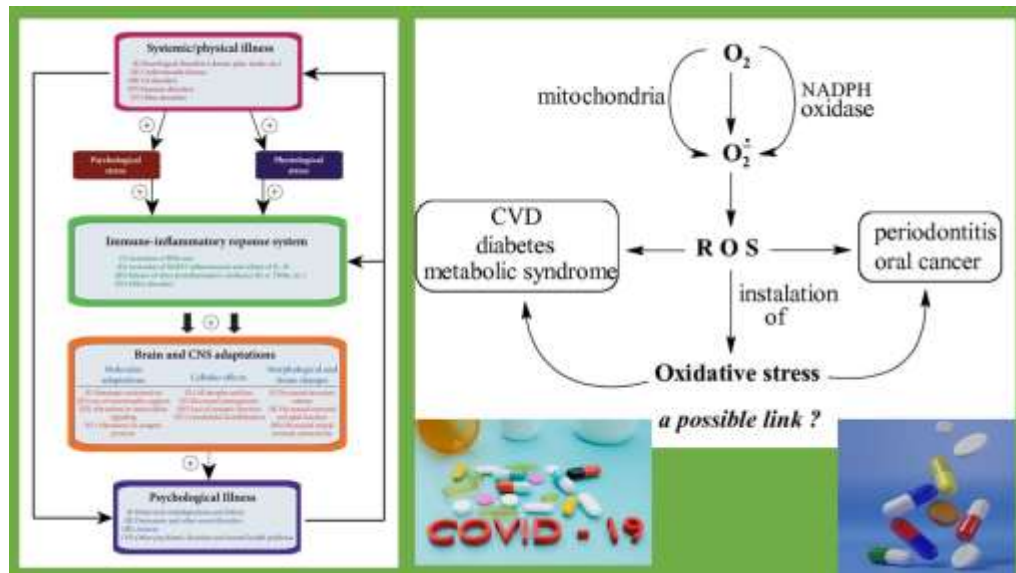
loss, gum nerve pain and even loose and broken teeth in people with systemic diseases. In these patients, there is usually no tooth decay or infection. Sometimes these patients complain of fatigue and pain in the muscles of the jaw and face, joint and teeth in the morning and after waking up. Sometimes these patients are unable to eat solid foods due to facial nerve pain and jaw pain. All of these can be the effects of teeth grinding or teeth grinding in sleep due to stress and anxiety during the day. Unfortunately, in the current situation, many people are under a lot of stress and anxiety (Figure 3). Among the side effects of high stress and anxiety are tooth nerve pain, jaw nerve pain and facial nerve pain caused by temporomandibular joint disorder. It is recommended for people who suffer from jaw nerve disorder and confusion to use stress reduction methods in the first stage and if these pains continue to go to the doctor to get the help of treatments such as wearing a tooth grinding

guard or Anti-inflammatory drugs treat this problem.

Primary tooth root infection

Maintaining oral and dental hygiene in children is inevitable. At the same time, most parents do not insist on oral-dental hygiene by children citing the temporary nature of milk teeth. It should be said that children's oral-dental problems and injuries also start from this point. In the previous discussions, we have discussed in detail the necessity of preserving milk teeth. Based on this topic, the most important role of milk teeth is a suitable growth pattern for permanent teeth. Many reasons and factors can cause tooth infection in children, but among these factors, there are two very important reasons that we will discuss below.

Figure 3. Bidirectional relationship between systemic illness and psychiatric
Tooth fracture



3035

Tooth Decay

One of the most important causes of tooth infection in children is tooth decay. If tooth decay is left untreated and worsens, the decay passes through the tooth enamel and dentin and reaches the tooth nerve. If treatment is not done in this situation despite severe dental pain, dental infections will occur. Naturally, when dental infections occur, they can be recognized and observed with symptoms such as severe pain, bad breath, swelling and many other symptoms.

The second most important cause of dental infections in children is broken teeth due to trauma, very hard foods, and grinding teeth. Fracture caused by any of the mentioned causes is one of the factors that involve the tooth nerve and this causes the leakage of food, saliva, and bacteria inside the mouth into the tooth, which ultimately leads to dental infections.

Symptoms of tooth infection in children

The symptoms of tooth infection in children are different according to the cause of this complication. Sometimes a child has all the



symptoms and sometimes some of them.

The most important signs and symptoms of tooth infection are:

Bad Breath.

Fever.

Unspecified pains inside the mouth that are so severe that the child is not able to accurately determine the origin of the pain.

Swelling inside the mouth.

Extraoral swelling, which can be very dangerous due to the possibility of infection spreading to the neck, head and face. A very important point that should not be forgotten is the location of the teeth in the head and face space. It should be mentioned that because these areas have a lot of vascular and nerve tissues, a simple dental infection can have irreparable consequences if the said tissues are not followed up.

Purulent discharge from the gums.

Reluctance to eat.

Another symptom of tooth infection is the child's reluctance to eat. Usually, the child is very anorexic, which causes him to lose weight gradually. Of course, it should be noted that since eating is very painful in children with acute dental infection, the child does not want to eat.

Oral tissue infection

Oral tissue infections are divided into soft tissue infections and hard tissue infections. In this topic, we will only deal with soft tissue infections. Soft tissue infections most often include intraoral herpes and canker sores, which are among the most common and common oral soft tissue infections in children. Naturally, the main cause of this type of infection is a virus that has no specific treatment, but with relatively symptomatic treatments, the burning of wounds and lesions caused by plague and herpes can be reduced so that the child can eat easily.

Treatment of oral soft tissue infections

If the child has soft oral tissue infections such as thrush and herpes, it is recommended to follow oral and dental hygiene even if the child refuses due to pain. Because this process prevents wounds from getting infected. Normally, oral ulcers and sores have a period of ten to fourteen days, after which they begin to heal. It should be noted that during this period, you should be careful about your child's nutrition, and also provide children with useful and beneficial foods, rich in vitamins and free of spices and pickles, high consumption of warm liquids. In some cases, it is observed that infections of oral soft tissues have not recovered after two weeks and the wounds are inflamed and painful. Regardless of the diseases of the immune system deficiency, this complication can be sustained due to the lack of oral hygiene and the exacerbation of oral infections.

Dental infections

One of the most important causes of dental infections are severe caries and tooth fractures. If the above-mentioned cases are not treated, the tooth nerve will be involved and we will see dental infections.

Search strategy and selection of articles

Search in Scopus, Google scholar, PubMed databases and by searching with keywords such as "Covid-19" and "Coronavirus 2019" and "Covid-19 and drugs" to obtain articles related to the selected keywords [43]. Case report articles, editorials, and articles that were not published or only an introduction of them were available, as well as summaries of congresses and meetings that were in languages other than English, were ignored. Only the original research articles that evaluated the effectiveness of different drugs in the treatment of COVID-19 using standard methods were studied (figure 4).



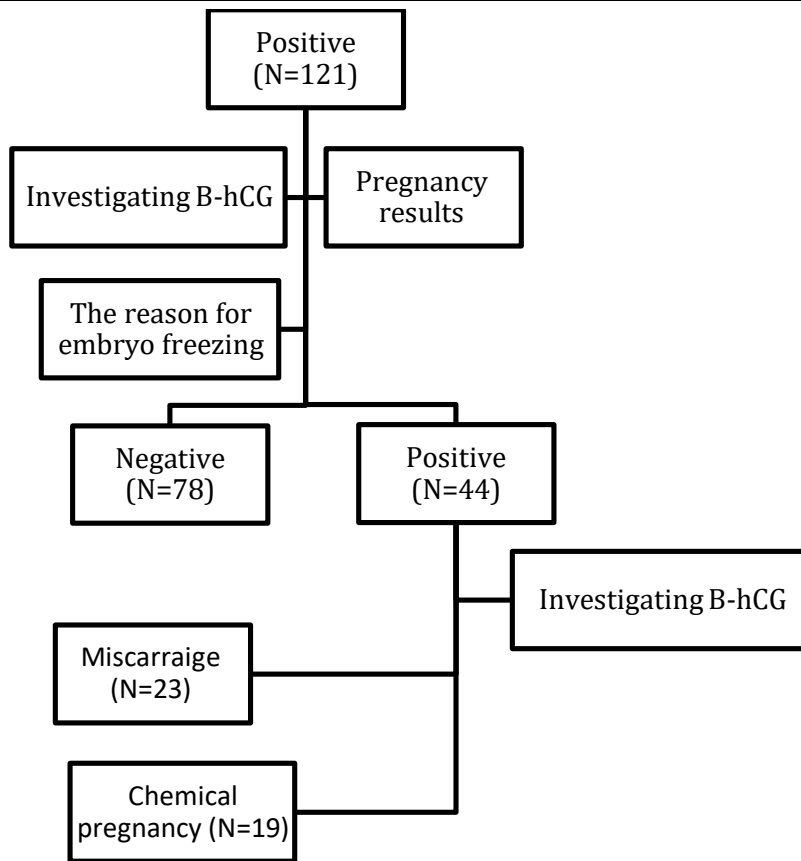


Figure 4. Flow chart of included subjects

Dental infections are divided into two categories, acute and chronic:

1- Acute dental infections: Acute dental infections appear as swelling around the teeth, swelling of the jaw and swelling of the face. It should be mentioned that these types of infections should be treated by a pediatric dentist as soon as possible. Treatment will be in the form of drug therapy and removal of lesions and infections. It should be noted that the treatment will not be effective only in the form of drug therapy and should be done along with the removal of lesions and infections.

2- Chronic dental infections: untreated acute infections turn into chronic infections over time. If the acute infection in the root of the tooth remains untreated, we will see a chronic infection in the area. A very important point that should be noted is that at the end of the root of the baby tooth, there is a permanent tooth bud, and any kind of infection should not be allowed to remain in the place and harm the permanent tooth bud.

Treatment of dental infections in children

Treatment methods for dental infections depend on

various factors such as the age of the child, the severity and extent of the infection, the length of time the target baby tooth remains in the mouth, the state of the permanent tooth bud, whether the tooth is anterior or posterior, the number of missing teeth. After examining various factors, treatment is done in the form of drug therapy and removal of lesions and infections, which must be done by a pediatric dentist, and arbitrary drug treatment leads to irreparable consequences for the child. Sometimes it is seen that parents arbitrarily use antibiotics to treat their child's tooth infection. This only increases the resistance of the child's body to the antibiotics used, and unfortunately, the child will have to take much stronger antibiotics in the future. It should also be mentioned that until the main source of the tooth infection is identified and treated by the dentist, taking any dose of antibiotics and even injecting antibiotics will not only help to treat the child's tooth infection, but will also cause the child's body to react to the antibiotic. be resistant This is while the swelling and inflammation of the gums may be



removed for a short period of time, but after a short period of time, it reappears.

Diagnosis of dental infection in children

The most important method of diagnosing oral-dental infections is a detailed examination of the soft and hard tissues of the mouth as well as the child's teeth in regular dental checkups. Normally, with a simple examination and the necessary investigations, as well as taking a history from the parents regarding the child's symptoms such as fever, anorexia, bad breath, swelling of the gums, swelling of the face, it is possible to find out the presence or absence of a tooth infection. If necessary, the children's dentist performs dental radiographs at the same time as complete intra-oral examinations.

Prevention of dental infection in children

The two basic principles in preventing oral-dental infections in children are:

Oral-dental hygiene: It is very clear that the child's nutrition starts from the mouth, and as long as the inside of the mouth is contaminated and the oral hygiene is not done, the contamination will enter the child's digestive system through the mouth, and that's it. This leads to the occurrence of many diseases such as oral thrush, frequent belching in babies, vomiting. It should be mentioned that the observance of oral and dental hygiene in children is one of the basic and very important principles that parents should observe from the beginning in order to significantly reduce the occurrence of many oral and dental diseases and even digestive problems. Another important factor in preventing oral and dental diseases, especially dental infections, is regular visits to children's dentists. Parents should visit a children's dentist right from infancy with the

eruption of the first milk tooth, so that they can

significantly prevent the occurrence of oral-dental diseases by receiving the necessary strategies for maintaining oral and dental hygiene.

Measures before treating dental infection in children

Before treating a tooth infection, do not do any treatment arbitrarily without consulting a pediatric dentist. Because arbitrary treatments can cause irreparable consequences. It should be mentioned that arbitrary treatments such as taking antibiotics cause the child's body to become resistant to this drug. Also, the use of hot and cold compresses can make the situation severe and acute, for example, the use of hot compresses in the case of an acute abscess can cause the infection to drain from the skin and irritate the child's face. The most important and correct thing you can do is to consult your child's dentist so that the appropriate treatment for your child can be prescribed and carried out. The only help for parents at this moment, until the children visit the dentist, is to observe oral and dental hygiene.

Care after treatment of dental infection in children

After treating the tooth infection, the children's dentist gives recommendations to the parents, and it is very important to follow each of these recommendations. It is obvious that the cooperation between the parents, the child and the children's dentist make the treatment process to be carried out correctly. When the medical recommendations are not fully followed, the treatment will surely fail. Therefore, it will be necessary to follow such recommendations after treatment (Figure 5).

3038



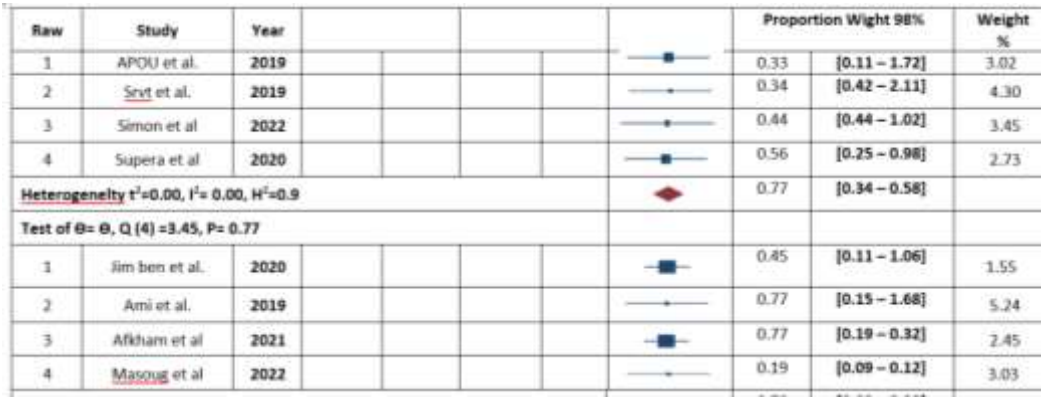


Figure 5. Forest plot showed Heart rate

Some recommendations of a pediatric dentist after treating a tooth infection include:

Use of prescribed medicines regularly at the prescribed time.

Use mouthwash and dental floss according to the children's dentist's instructions.

Not consuming certain foods due to their excessive stiffness or stickiness.

The pain you feel after tooth extraction may be due to an infection in the extracted area. In this case, the infection must first be completely cleaned and then completely sealed and completely repaired with filling materials. If the bacteria remain inside the bone and around the root, it will cause more pain and inflammation. This is if there are still bacteria hidden in that part despite complete cleaning, and this remaining bacterium is destroyed by using antibiotics and the body's immune system. If the crown is too small or the tooth filling is done a little more, it will put pressure on the tooth wall and cause pain in the root area of the tooth, which can be removed without worry. In this way, excessive filling can be removed or the cover can be adjusted, but in this case, you will feel pain for more than 5 days. Teeth have several channels, which are sometimes very difficult to distinguish.

Especially in molars, it is very difficult to recognize the canal. It is normal that sometimes the dentist, using a general look at the infected canal, left some nerves inside the tooth with bacteria and infection and did not notice it. If this has happened and the nerve is left alone, it is possible that the tooth will become more sensitive to cold and heat, while if it has an infection, it will also become sensitive to pressure. In this case, the feeling of pain will continue for more than 5 days, and for treatment, you should visit your dentist as soon as possible so that root canal treatment and denervation can be done again. One of the most important symptoms seen for denervation is a very intense pain in the tooth. The pain you feel in your tooth indicates that a process has gone wrong inside the root of your tooth. Now, you may feel this pain when drinking very cold liquids or very hot liquids, which you should visit the dentist as soon as possible to solve it (Figure 6). You may feel a tingling sensation in that area after drinking hot or cold liquids. In order to prevent tooth decay and damage to the dental nerve in adulthood, it is better to perform fissure sealant at a younger age. If the dentist fails to find all the root canals and is unable to clean or re-nerve them, re-nerving is required.

3039

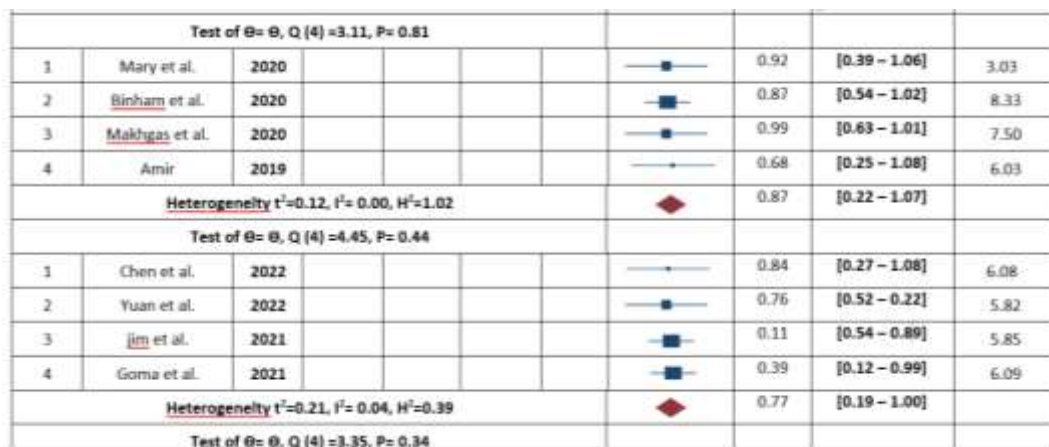


Figure 6. Forest plot showed Body temperature

These additional canals may not be evident in paraclinical examinations, and additional canals or unenervated canals may be found when fillings are removed by the dentist. In this case, the patient is advised to re-nerve the tooth. Also, in cases where the denervation of the tooth is incomplete, that is, the end of the canal has not been cleaned and the root of the tooth has not been opened, paraclinical observations can be used.

Conclusion

When dentists work on your teeth, operations such as pediatric dentistry, dental laminates, dental implants, dental orthodontics, etc. or for example during tooth grinding with a turbine or when scaling and polishing teeth with polishing brushes, aerosols, suspended droplets It is created in the air from saliva or blood. Under normal circumstances, dentists are required to assume that all patients are infected with infectious diseases and to take precautionary measures in the field of infection control for all patients in order to reduce the risk of transmission of infectious respiratory and blood diseases. These precautions keep both patients and dentists safe, but despite the corona virus epidemic, the risk of virus-carrying aerosols during dental procedures has increased, which either directly infects the office staff or by sitting on a surface that Touched by staff or subsequent patients, it causes disease transmission. Transmission is possible even in apparently healthy patients. Because not all people infected with the virus have symptoms of corona disease. Therefore, infection control and the implementation of special measures for disinfection become especially important during the period when the corona virus is spreading. Australia's main committee on health protection and the main committee on decision-making in emergencies recently advised dentists to only perform treatments where the generation of airborne particles is zero or limited, and that all routine examinations and treatments should be postponed. to fall According to Australian Dental Association guidelines, level three restrictions should apply. These recommendations may change over time. Root canal or root canal treatment is a problem that most people will experience at least once in their life. Of course, many people are anxious about doing this treatment process and think that it is a very painful procedure. The

method of tooth extraction is to clean the root of the tooth and also shape the root canal. During the treatment, the path of the root canal of the tooth is blocked with special materials so that no microbes can infect the root of the tooth and the percentage of their growth is as minimal as possible. The area around the tooth that is treated will definitely become more sensitive, and for this reason, you may experience pain and discomfort for 3 to 5 days after the procedure.

References

- Abbasi, M. Nakhostin, A. Namdar F. Chiniforush, N. Hasani Tabatabaei, M. The Rate of Demineralization in the Teeth Prepared by Bur and Er:YAG Laser, *J Lasers Med Sci.* 9(2):82-86. (2018)
- Abreu GA, Aguilar MH, Covarrubias DH, Durán FR. Amantadine as a drug to mitigate the effects of COVID-19. *Med Hypotheses.* 2020;140:109755.
- Ahamed S, Samad M. Information mining for covid-19 research from a large volume of scientific literature. *arXiv preprint arXiv:200402085.* 2020.
- Al-Tawfiq JA, Al-Homoud AH, Memish ZA. Remdesivir as a possible therapeutic option for the COVID-19. *Travel medicine and infectious disease.* 2020.
- Beachboard, D.C., J.M. Anderson-Daniels, and M.R. Denison, Mutations across murine hepatitis virus nsp4 alter virus fitness and membrane modifications. *J Virol,* 2015. 89(4): p. 9-2080.
- Beigel JH, Tomashek KM, Dodd LE, Mehta AK, Zingman BS, Kalil AC, et al. Remdesivir for the treatment of Covid-19—preliminary report. *The New England journal of medicine.* 2020.
- Borba MGS, Val FFA, Sampaio VS, Alexandre MAA, Melo GC, Brito M, et al. Effect of high vs low doses of chloroquine diphosphate as adjunctive therapy for patients hospitalized with severe acute respiratory syndrome coronavirus 2 (SARS-CoV-2) infection: a randomized clinical trial. *JAMA network open.* 2020;3(4):e208857-e.
- Cai Q, Yang M, Liu D, Chen J, Shu D, Xia J, et al. Experimental treatment with favipiravir for COVID-19: an open-label control study. *Engineering.* 2020.
- Cascella M, Rajnik M, Cuomo A, Dulebohn SC, Di Napoli R. Features, evaluation and treatment coronavirus (COVID-19). *Statpearls [internet]: StatPearls Publishing;* 2020.
- Chen, Y., Liu, Q. & Guo, D. Emerging coronaviruses: genome structure, replication, and pathogenesis. *J. Med. Virol.* <https://doi.org/10.1002/jmv.25681> (2020).
- Chiusano ML. The modelling of COVID19 pathways sheds light on mechanisms, opportunities and on controversial interpretations of medical treatments. v2. *arXiv preprint arXiv:200311614.* 2020.
- Cottam, E.M., M.C. Whelband, and T. Wileman, Coronavirus NSP6 restricts auto-phagosome expansion. *Autophagy,* 2014. 10(8): p. 1426-41.
- Crisan D, Carr J. Angiotensin I-converting enzyme: genotype and disease associations. *J of Mol Diagn.* 2000; 2(3): 105.
- Dong E, Du H, Gardner L. An interactive web-based dashboard to track COVID-19 in real time. *The Lancet infectious*



- diseases. 2020;20(5):533-4.
- Furuta Y, Gowen BB, Takahashi K, Shiraki K, Smee DF, Barnard DL. Favipiravir (T-705), a novel viral RNA polymerase inhibitor. *Antiviral research.* 2013;100(2):446-54.
- Gadlage, M.J., et al., Murine hepatitis virus nonstructural protein 4 regulates virus-induced membrane modifications and replication complex function. *J Virol.* 2010. 84(1): p. 280-90.
- Gao J, Tian Z, Yang X. Breakthrough: Chloroquine phosphate has shown apparent efficacy in treatment of COVID-19 associated pneumonia in clinical studies. *Bioscience trends.* 2020.
- Graham, R.L., et al., The nsp2 replicas' proteins of murine hepatitis virus and severe acute respiratory syndrome coronavirus are dispensable for viral replication. *J Virol.* 2005. 79(21): p. 13399-411.
- Hao Xu. High expression of ACE2 receptor of 2019-nCoV on the epithelial cells of oral mucosa. *International Journal of Oral Science* (2020) 12:8; <https://doi.org/10.1038/s41368-020-0074-x>.
- Helmy YA, Fawzy M, Elasad A, Sobieh A, Kenney SP, Shehata AA. The COVID-19 pandemic: a comprehensive review of taxonomy, genetics, epidemiology, diagnosis, treatment, and control. *Journal of Clinical Medicine.* 2020;9(4):1225.
- Hosseini Khalili AR, Thompson J, Kehoe A, Hopkinson NS, et al. Angiotensin-converting enzyme genotype and late respiratory complications of mustard gas exposure. *BMC Pulm Med.* 2008;8(1):15.
- Huang L, Zhang X, Zhang X, Wei Z, Zhang L, Xu J, et al. Rapid asymptomatic transmission of COVID-19 during the incubation period demonstrating strong infectivity in a cluster of youngsters aged 16-23 years outside Wuhan and characteristics of young patients with COVID-19: a prospective contact-tracing study. *Journal of Infection.* 2020.
- Huang, C., et al., SARS coronavirus nsp1 protein induces template-dependent endonucleolytic cleavage of mRNAs: viral mRNAs are resistant to nsp1-induced RNA cleavage. *PLoS Pathog.* 2011. 7(12): p. e1002433.
- Ibrahim IM, Abdelmalek DH, Elshahat ME, Elfiky AA. COVID-19 spike-host cell receptor GRP78 binding site prediction. *Journal of Infection.* 2020.
- Jiahua He Huanyu Tao, Yumeng Yan, Sheng-You Huang*, Yi Xiao. Molecular mechanism of evolution and human infection with the novel coronavirus (2019-nCoV). *bioRxiv preprint* doi: <https://doi.org/10.1101/2020.02.17.952903>.
- Kalantari H, Tabrizi AHH, Foroohi F. Determination of COVID-19 prevalence with regards to age range of patients referring to the hospitals located in western Tehran, Iran. *Gene reports.* 2020;21: 100910.
- Karampela I, Dalamaga M. Could Respiratory Fluoroquinolones, Levofloxacin and Moxifloxacin, Prove to be Beneficial as an Adjunct Treatment in COVID-19? *Archives of medical research.* 2020;51(7):741-2.
- Khosraviyani, F. Saberi-Demneh, A. Asadollahifar, R. Nakhostin, A. Khazaei P. Post-operative pain management with meloxicam: a systematic literature review in the field of dentistry, *Oral Surgery,*
- Kirchdoerfer, R.N. and A.B. Ward, Structure of the SARS-CoV nsp12 polymerase bound to nsp7 and nsp8 co-factors. *Nat Commun.* 2019. 10(1): p. 2342.
- Lei, J., Y. Kusov, and R. Hilgenfeld, Nsp3 of coronaviruses: Structures and functions of a large multi-domain protein. *Antiviral Res.* 2018. 149: p. 58-74.
- Lim J, Jeon S, Shin H-Y, Kim MJ, Seong YM, Lee WJ, et al. Case of the index patient who caused tertiary transmission of COVID-19 infection in Korea: the application of lopinavir/ritonavir for the treatment of COVID-19 infected pneumonia monitored by quantitative RT-PCR. *Journal of Korean medical science.* 2020;35(6).
- Liu W, Morse JS, Lalonde T, Xu S. Learning from the past: possible urgent prevention and treatment options for severe acute respiratory infections caused by 2019-nCoV. *ChemBiochem.* 2020.
- Lu, R. et al. Genomic characterization and epidemiology of 2019 novel coronavirus: implications for virus origins and receptor binding. *Lancet.* [https://doi.org/10.1016/S0140-6736\(20\)30251-8](https://doi.org/10.1016/S0140-6736(20)30251-8) (2020).
- Madelain V, Oestereich L, Graw F, Nguyen THT, De Lamballerie X, Mentré F, et al. Ebola virus dynamics in mice treated with favipiravir. *Antiviral research.* 2015;123:70-7.
- Montani JP, Vliet VB. General physiology and pathophysiology of the renin-angiotensin system. *Angiotensin Vol. I: Springer;* 2004: 3-29.
- Monteil V, Dyczynski M, Lauschke VM, Kwon H, Wirnsberger G, Youhanna S, et al. Human soluble ACE2 improves the effect of remdesivir in SARS-CoV-2 infection. *EMBO molecular medicine.* 2020:e13426.
- Rothan HA, Byrareddy SN. The epidemiology and pathogenesis of coronavirus disease (COVID-19) outbreak. *Journal of autoimmunity.* 2020:102433.
- Samiei, N. Ghane, HK. Khaled, Y. COVID-19 and Periodontal Disease: The Potential Role of Interleukin-6, *SVOA Dentistry,* 2(6), 254-257, (2021)
- Serrano, P., et al., Nuclear magnetic resonance structure of the nucleic acid-binding domain of severe acute respiratory syndrome coronavirus nonstructural protein 3. *J Virol.* 2009. 83(24): p. 12998-3008.
- Singh AK, Singh A, Shaikh A, Singh R, Misra A. Chloroquine and hydroxychloroquine in the treatment of COVID-19 with or without diabetes: A systematic search and a narrative review with a special reference to India and other developing countries. *Diabetes & Metabolic Syndrome: Clinical Research & Reviews.* 2020.
- Smieszek SP, Przychodzen BP, Polymeropoulos MH. Amantadine disrupts lysosomal gene expression; a hypothesis for COVID19 treatment. *International Journal of Antimicrobial Agents.* 2020:106004.
- Sohrabi C, Alsafi Z, O'Neill N, Khan M, Kerwan A, Al-Jabir A, et al. World Health Organization declares global emergency: A review of the 2019 novel coronavirus (COVID-19). *International Journal of Surgery.* 2020.
- Spinner CD, Gottlieb RL, Criner GJ, López JRA, Cattelan AM, Viladomiu AS, et al. Effect of remdesivir vs standard care on clinical status at 11 days in patients with moderate COVID-19: a randomized clinical trial. *Jama.* 2020;324(11):1048-57.
- Stobart, C.C., et al., Chimeric exchange of coronavirus nsp5 proteases (3CLpro) identifies common and divergent regulatory determinants of protease activity. *J Virol.* 2013. 87(23): p. 12611-28.
- Stoessel AJ, Bhatia KP, Merello M. Movement Disorders in the World of COVID-19. *Movement Disorders Clinical Practice.* 2020;7(4):355-6.
- Tanaka, T., et al., severe acute respiratory syndrome coronavirus nsp1 facilitates efficient propagation in cells



- through a specific translational shutoff of host mRNA. *J Virol*, 2012. 86(20): p. 11128-37.
- Tchesnokov EP, Gordon CJ, Woolner E, Kocinkova D, Perry JK, Feng JY, et al. Template-dependent inhibition of coronavirus RNA-dependent RNA polymerase by remdesivir reveals a second mechanism of action. *Journal of Biological Chemistry*. 2020;295(47):16156-65.
- Uzunova K, Filipova E, Pavlova V, Vekov T. Insights into antiviral mechanisms of remdesivir, lopinavir/ritonavir and chloroquine/hydroxychloroquine affecting the new SARS-CoV-2. *Biomedicine & Pharmacotherapy*. 2020:110668.
- Velavan TP, Meyer CG. The COVID-19 epidemic. *Tropical medicine & international health*. 2020;25(3):278.
- Wang D, Hu B, Hu C, Zhu F, Liu X, Zhang J, et al. Clinical characteristics of 138 hospitalized patients with 2019 novel coronavirus-infected pneumonia in Wuhan, China. *Jama*. 2020;323(11):1061-9.
- Wang M, Cao R, Zhang L, Yang X, Liu J, Xu M, et al. Remdesivir and chloroquine effectively inhibit the recently emerged novel coronavirus (2019-nCoV) in vitro. *Cell research*. 2020;30(3):269-71.
- Warren T, Jordan R, Lo M, Soloveva V, Ray A, Bannister R, et al, editors. Nucleotide prodrug GS-5734 is a broad-spectrum filovirus inhibitor that provides complete therapeutic protection against the development of Ebola virus disease (EVD) in infected non-human primates. *Open Forum Infectious Diseases*; 2015: Infectious Diseases Society of America.

